

*understanding*  
**SPECIAL**  
**EMBRYOLOGY**

**BY**  
**DR. SAMEH DOSS (Ph.D)**

**PROFESSOR OF ANATOMY**  
**FACULTY OF MEDICINE , CAIRO UNIVERSITY**

*understanding*  
**SPECIAL**  
**EMBRYOLOGY**

BY  
**DR. SAMEH DOSS (Ph.D)**

**PROFESSOR OF ANATOMY**  
**FACULTY OF MEDICINE , CAIRO UNIVERSITY**

National Library Legal Deposit  
22430/ 2014

I.S.B.N.  
978-977-90-2322-9



# DEVELOPMENT OF THE HEART

1

**\*Origin:** It develops from the splanchnic mesoderm.

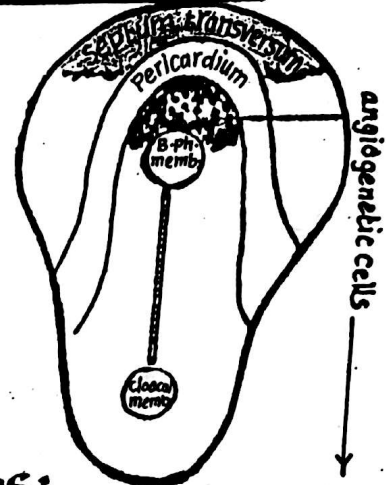
**\*Site :** Cardiogenic area in front of buccopharyngeal membrane.

**\*Time of appearance:** during the 3<sup>rd</sup> week.

## A- THE EXTERNAL FORM OF THE HEART

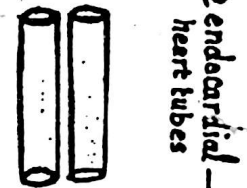
### (1) primordium of the heart :

- the primordium of the heart is represented by a group of mesodermal cells called angiogenetic cells which lie in the ant. (cephalic) part of the embryonic disc in front of the buccopharyngeal membrane
- When the head fold is formed, the heart primordium becomes ventral in position.



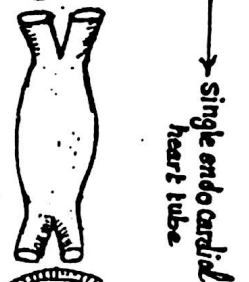
### (2) Formation of 2 endocardial heart tubes:

- the angiogenetic cells will give rise to 2 endocardial heart tubes which lie very close to each other in the middle line



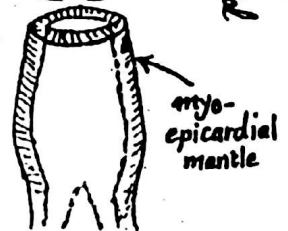
### (3) Formation of single endocardial heart tube:

the 2 endocardial heart tubes soon unite together forming a single heart tube which will form the endocardium of the heart.



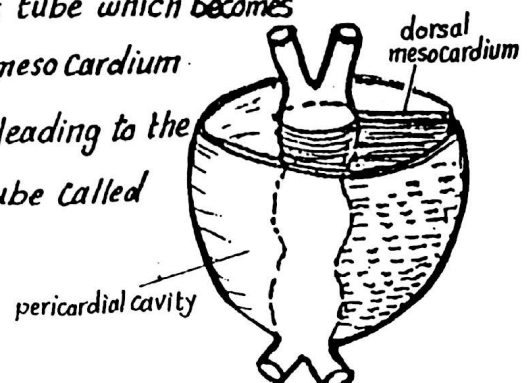
### (4) Formation of the myocardium & the epicardium:

the splanchnic mesoderm surrounds the endocardial heart tube forming myoepicardial mantle which differentiates into the myocardium & the epicardium of the heart.



(5) The Pericardial Cavity surrounds the heart tube which becomes suspended to the roof of the cavity by the dorsal mesocardium.

(6) the dorsal mesocardium disappears later on leading to the formation of a passage dorsal to the heart tube called the transverse sinus of the pericardium.



## (7) Differentiation of the heart tube into 4 Chambers:

2

3 constrictions appear in the primitive heart tube dividing it into 4 dilatations (primitive chambers):

### (a) Bulbus cordis:

is the most cranial part of the heart tube. Its upper end is called the truncus arteriosus which gives rise to aortic arches.

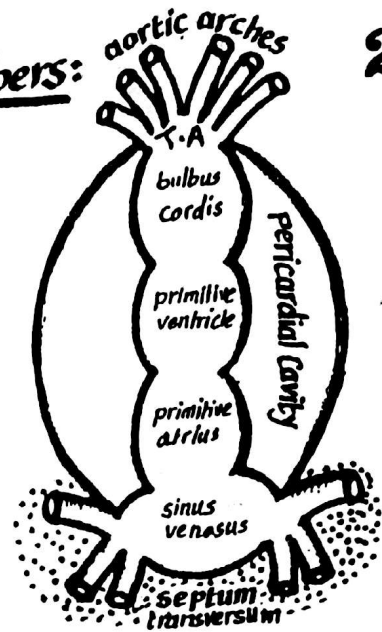
### (b) the primitive ventricle (Common ventricle):

lies below the bulbus cordis

### (c) the primitive atrium (Common atrium):

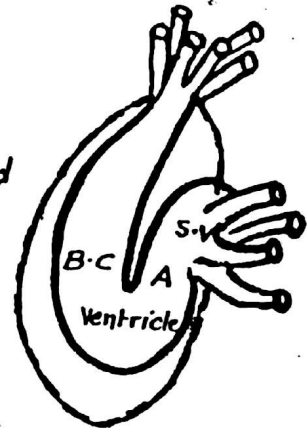
lies below the common ventricle

(d) the Sinus Venosus: is the most caudal part of the heart tube. It is formed of a median part & 2 horns (Rt. & Lt.) receiving the veins. The sinus venosus lies at first embedded in the septum transversum but later separates from it.



## (8) Formation of U-shaped heart tube:

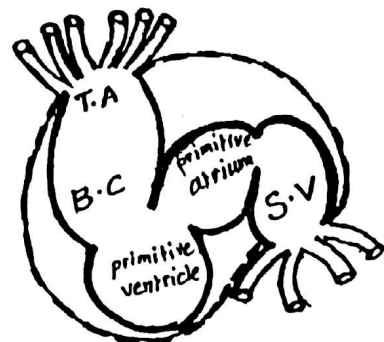
- the heart tube grows much faster than the pericardium so, it becomes folded to form a U-shaped tube
- the ventricle now lies below both bulbus cordis & the primitive atrium



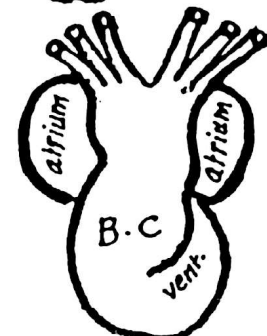
## (9) Formation of S-shaped heart tube:

as a result of the rapid growth of the cardiac loop, it becomes S-shaped having:

- the bulbus cordis lying in front & to the Rt. side
- the primitive ventricle " " & to the Lt. " of the primitive atrium
- the Sinus venosus lies behind the primitive atrium



Side View



Front View



# B- THE INTERNAL STRUCTURE OF THE HEART

3

## 1-- FATE OF THE SINUS VENOSUS

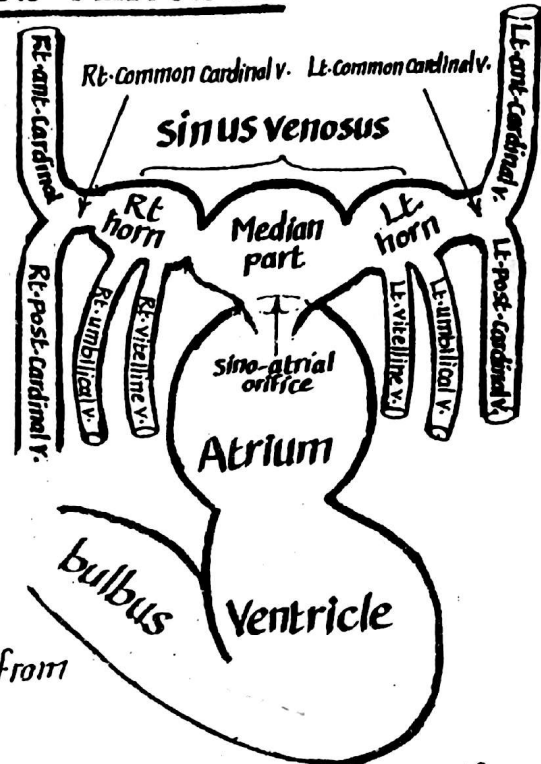
\* The Sinus venosus is the most caudal part of the heart tube & receives all the veins of the body of the foetus.

\* Structure: it is formed of a small median part & 2 Lat. horns: Rt. & Lt.:

\* Each horn receives the following veins:

- (1) Vitelline vein: from the yolk sac.
- (2) Umbilical vein: from the placenta.
- (3) Common Cardinal vein (formed by the union of the ant. & post. Cardinal veins) from the body of the embryo itself

\* The Sinus venosus opens into the primitive atrium by a sino-atrial orifice guarded by Rt. & Lt. valves.

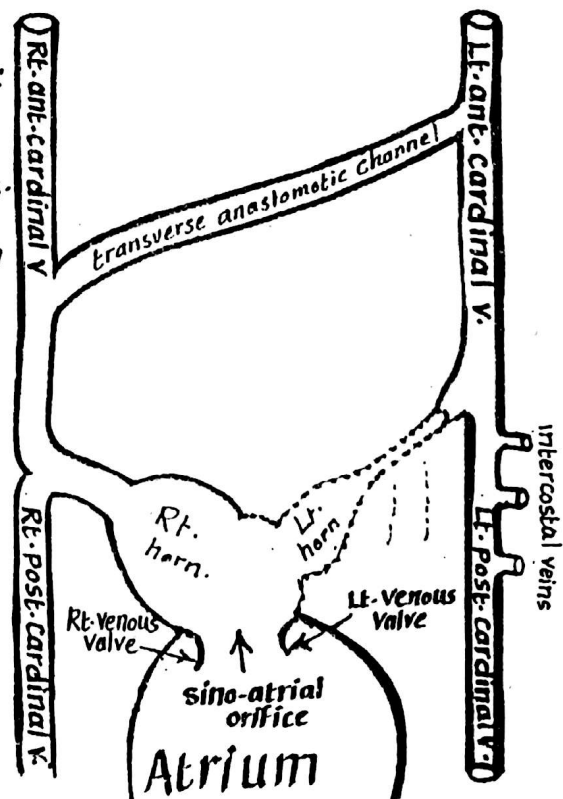


## \* CHANGES OCCURING IN THE SINUS VENOSUS

(1) The Lt. sinus horn diminishes in size due to decreased blood reaching it because:

- (a) both Lt. vitelline & Lt. umbilical veins lose their connection with the sinus venosus.
- (b) transverse anastomoses develop shifting blood from the Lt.-sided veins to the Rt.-sided veins and as a result:

- the Lt. sinus horn becomes smaller & forms the Coronary sinus
- the Lt. Common Cardinal v. forms the oblique v. of Lt. atrium (which ends in the Coronary sinus).



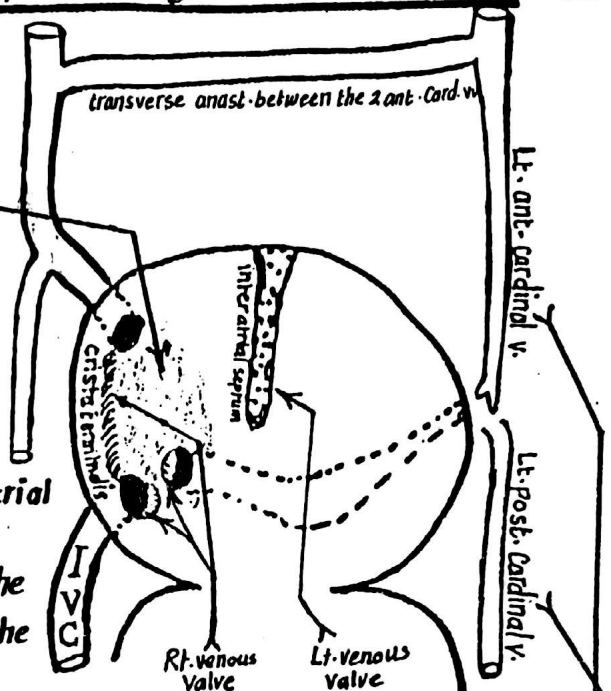
## (2) Fate of the Rt. horn & the median part (body) of Sinus Venosus: 4

they become absorbed into the Rt. side of the primitive common atrium & will later form the post-smooth part of the Rt. atrium (called the sinus venarum).

- NB** - the Rt. umbilical v.: disappears completely.  
 - the Rt. vitelline v. forms the uppermost part of the I.V.C.

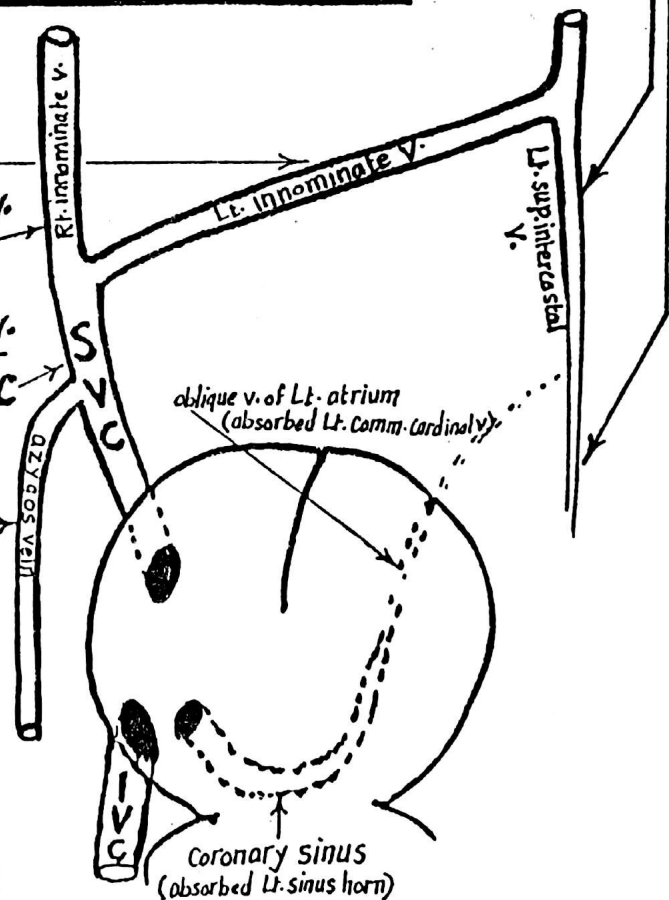
## (3) Fate of the Rt. & Lt. Venous Valves of the sinoatrial orifice:

- the Lt. venous valve: fuses with the interatrial septum.
- the Rt. venous valve: its upper part forms the crista terminalis while its lower part forms the valves of the I.V.C & the coronary sinus.
- the septum spurium which is formed by the fusion of the Rt. & Lt. venous valves at the cranial end of the sinoatrial orifice: forms the lower part of crista terminalis



## (4) Fate of the Veins draining into the sinus venosus:

- the transverse anastomosis between the 2 ant. cardinal veins will form the left innominate vein.
- the upper part of the Rt. ant. cardinal v. forms the Rt. innominate v.
- the lower part of the Rt. ant. cardinal v. + the Rt. common cardinal v. form the S.V.C
- the whole Rt. post. cardinal v.: forms the upper part of the azygos v.
- the Lt. common cardinal v.: forms the oblique v. of Lt. atrium.
- the Lt. ant. cardinal vein: forms the Lt. sup. intercostal v.
- the Lt. post. cardinal v.: forms the distal part of the Lt. sup. intercostal vein.





## 5

A hand-drawn diagram illustrating the pulmonary circulation. At the top, two teardrop-shaped lungs are labeled "Rt. Lung" and "Lt. Lung". They are connected by a network of vessels to a central point labeled "Common pulmonary V.". This vessel leads down to a large circle representing the "atrium". Below the atrium is a structure labeled "ventricle", which is shown with a cross-section revealing internal layers. A bracket on the right side of the ventricle is labeled "endocardial cushion", with "dorsal" and "ventral" labels pointing to the upper and lower parts of the cushion respectively.

Common atrium

Common pulmonary V.

A-V Canal

Common ventricle

dorsal / ventral } endocardial cushion

- endocardial cushions  $\xrightarrow{\text{fusion}}$  Septum intermedium

The diagram illustrates the development of the heart in a vertebrate embryo, showing the transition from a simple heart tube to a complex four-chambered heart.

**Top Diagram (Early Stage):** Shows a simple heart tube with a **sinoatrial orifice** at the top. The heart is divided into a **Rt. atrium** (right atrium) and a **Lt. atrium** (left atrium) by the **Septum primum**. Below the atria are the **Rt. A-V canal** (right atrioventricular canal) and the **Lt. A-V canal** (left atrioventricular canal). The **atrium. border** is indicated on the left.

**Middle Diagram (Intermediate Stage):** Shows the heart tube with the **Septum primum** and the **ostium primum** (primary opening) between the atria. The **ostium secundum** (secondary opening) is also visible. The **dorsal horn** and **ventral horn** are labeled.

**Bottom Diagram (Late Stage):** Shows the heart tube with the **Septum primum** and the **ostium primum** and **ostium secundum** openings. The **closure** of the ostium primum is indicated.

(A)-the Septum primum

- 
- The diagram illustrates the internal anatomy of a bivalve shell, divided into two views of the valves. The upper valve (dorsal view) shows the **septum primum** (primary septum) and the **ostium primum** (primary siphon). The lower valve (ventral view) shows the **ostium secundum** (secondary siphon) and the **closure** mechanism. The **dorsal horn** and **ventral horn** are also labeled. The diagram is a black and white line drawing with labels in Latin and English.

## (B)- Septum Secundum

\* it appears after the formation of the septum primum.

\* Shape: like septum primum, it is sickle-shaped having a lower crescentic edge with 2 horns (ventral & dorsal).

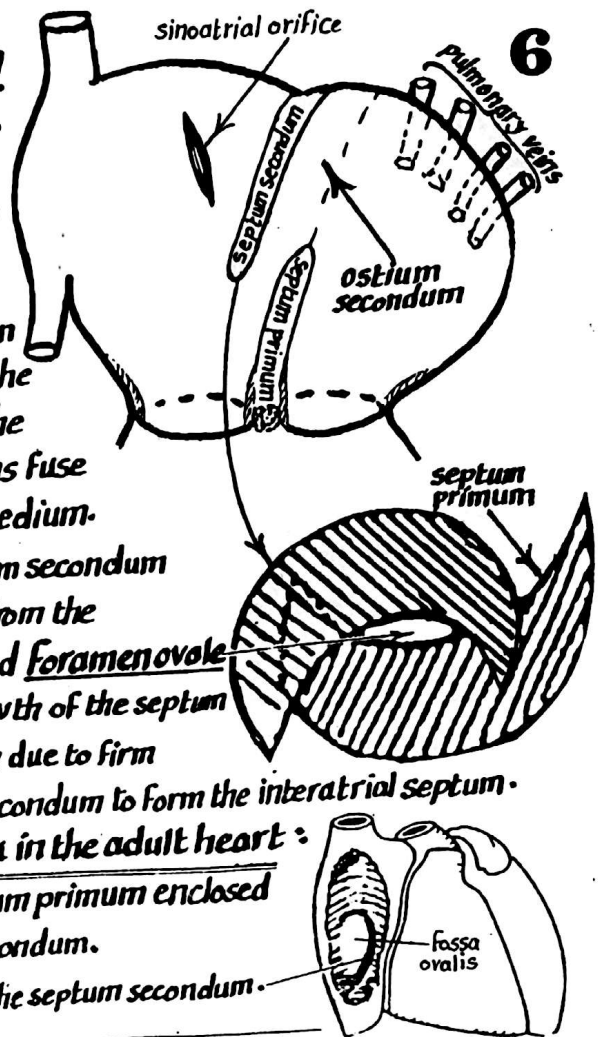
\* Origin & Course: it arises from the roof of the common atrium (on the Rt. side of the septum primum & to the Lt. of the sinoatrial orifice) & descends caudally in the direction of the septum intermedium until its 2 horns fuse with the endocardial cushions of the septum intermedium.

\* Fate: the septum secundum overlaps the ostium secundum but its caudal crescentic edge is still separated from the cephalic free edge of septum primum by a gap called Foramen ovale which gradually gets narrower by the caudal growth of the septum secundum. The foramen ovale finally closes at birth due to firm apposition & fusion between the septum primum & secundum to form the interatrial septum.

\* Embryological remnants of the 2 foetal Septa in the adult heart:

(a) fossa ovalis: represents the part of the septum primum enclosed by the 2 horns of the septum secundum.

(b) annulus ovalis: represents the free caudal edge of the septum secundum.



(3) Absorption of the Atrio-Ventricular Canals into the atria:

each of the Rt. & the Lt. atrioventricular canal becomes absorbed into the corresponding atrium.

(4) Absorption of the Pulmonary veins into the Lt. atrium:

- At first, a single pulmonary v. opens into the dorsal wall of the Lt. atrium. This single v. is formed by the union of Rt. & Lt. Veins each of which is formed by 2 veins emerging from a lung.
- Later on, the stem of the common pulmonary v. & its 2 tributaries become absorbed into the wall of the Lt. atrium & thus the 4 pulmonary veins open separately into the Lt. atrium.

## EMBRYOLOGICAL COMPONENTS OF EACH ATRIUM

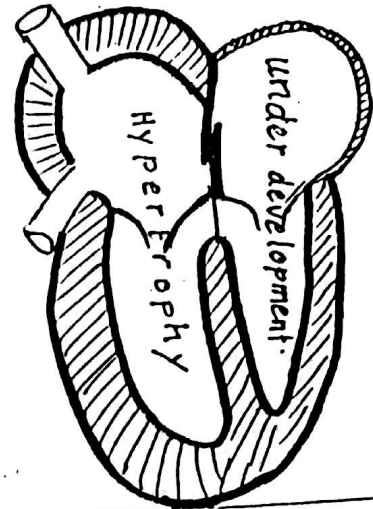
Components of the Rt. atrium	Components of the Lt. atrium
(1) the Rt. $\frac{1}{2}$ of the common atrium: forms the rough ant. part + the auricle	(1) the Lt. $\frac{1}{2}$ of the common atrium: forms the auricle of the Lt. atrium
(2) the absorbed Rt. A-V canal	(2) the absorbed Lt. A-V canal } form the remaining smooth part
(3) the absorbed sinus venosus } form the post-smooth part of the atrium.	
	(3) the absorbed pulm. veins }



# ANOMALIES OF THE INTERATRIAL SEPTUM 7

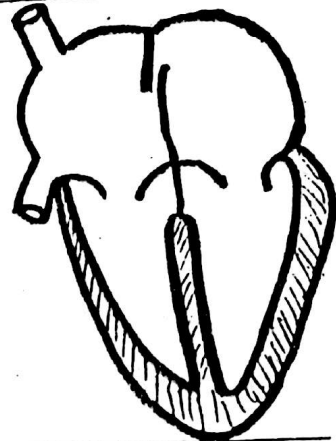
## (1) Premature Closure of foramen ovale:

- \* This anomaly is characterized by premature closure of foramen ovale in the intra uterine life.
- \* This is a serious anomaly leading to massive hypertrophy of Rt. atrium & Rt. ventricle with underdevelopment of Lt. atrium & Lt. ventricle.
- \* This anomaly usually leads to the death of the foetus shortly after birth.




## (2) Probe patent foramen ovale:

- \* Normally, the foramen ovale closes completely at birth.
- \* In 20-25% of people, a probe can be passed through the foramen ovale.
- \* In this anomaly the defect is so small that blood cannot pass between the 2 atria.



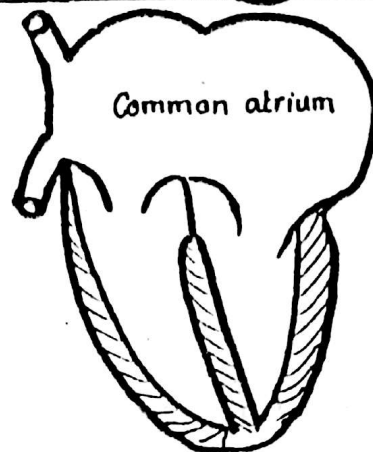
## (3) Ostium secundum defect:

- \* This is a serious anomaly in which there is a large opening between the 2 atria.
- \* It is due to either:
  - (a) excessive resorption of septum primum or
  - (b) improper formation of septum secundum.
- \* This anomaly leads to cyanosis.



## (4) Complete failure of formation of the interatrial septum:

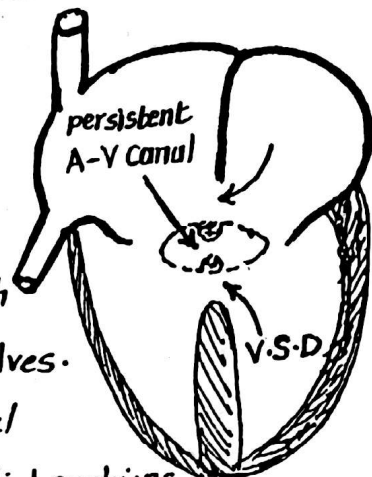
- \* This is the most serious anomaly of this group where both septum primum & septum secundum fail to develop.
- \* The heart is thus formed of 3 chambers: Common atrium & 2 ventricles i.e. trilocular heart.



# ANOMALIES OF THE ATRIOVENTRICULAR CANAL 8

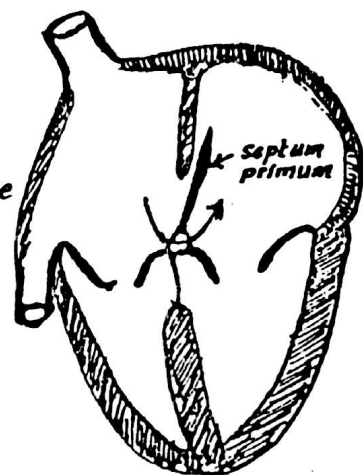
## (1) Persistent atrio-ventricular canal :

- \* This anomaly is due to Complete failure of fusion of the ant. & post. endocardial cushions leading to failure of formation of the septum intermedium which normally divides the atrio-ventricular canal into 2 halves.
- \* This anomaly is usually accompanied by Atrial septal defect & interventricular septal defect as the endocardial cushions share in the formation of the inter atrial & Interventricular Septa.



## (2) Ostium Primum defect :

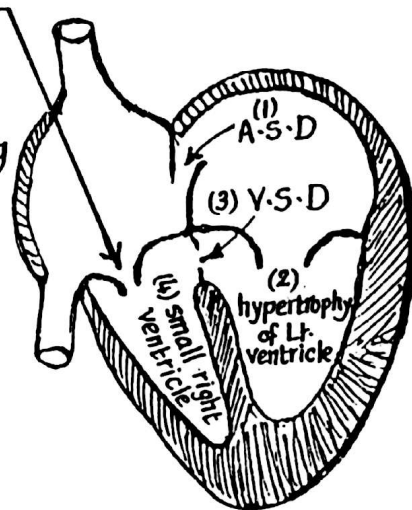
- \* This is due to partial (incomplete) fusion of the ant. & post. endocardial cushions leading to defective formation of the septum intermedium.
- \* The Septum primum fails to join the septum intermedium leading to failure of closure of the ostium primum.



## (3) Tricuspid atresia :

- \* This anomaly is due to fusion of the cusps of the tricuspid valve leading to its narrowing
- \* This anomaly is usually accompanied by:

- (1) Patent foramen ovale
- (2) hypertrophy of Lt. ventricle.
- (3) patent interventricular foramen.
- (4) small Rt. ventricle.





### 3-- DEVELOPMENT OF THE BULBOVENTRICULAR REGION<sup>9</sup>

(1) The bulbus cordis lies at first to the right side of the primitive common ventricle with a deep sulcus inbetween them.

(2) the sulcus between the common ventricle & the bulbus cordis becomes gradually obliterated.

(3) the bulbus cordis moves to the left to lie in front of the common ventricle.

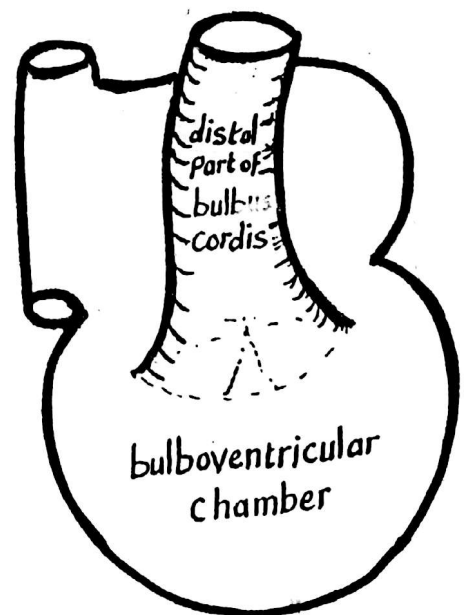
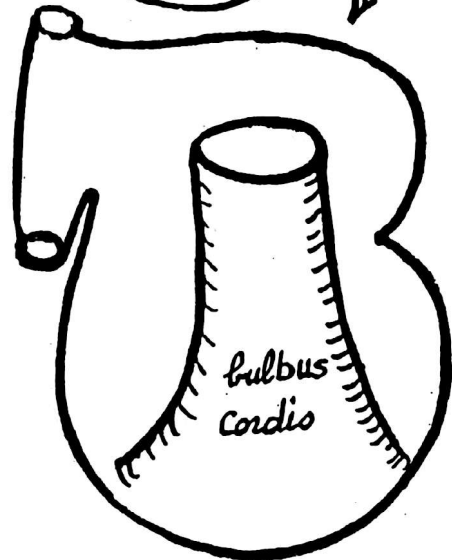
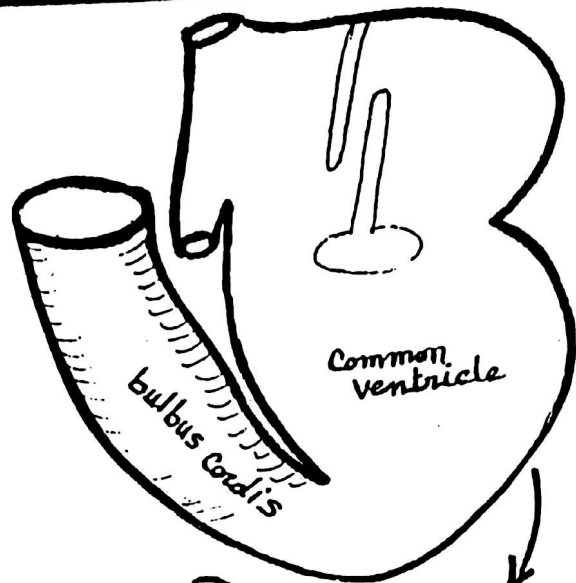
(4) the proximal part of the bulbus becomes absorbed inside the primitive ventricle to form the common bulboventricular chamber

#### \* Fate of the bulbus Cordis :

(1) Its proximal part : forms the trabecular part of the Rt. ventricle.

(2) its middle part : forms the outflow tracts of the Rt. & Lt. ventricles ( the infundibulum of the Rt. ventricle & the vestibule of the Lt. ventricle.

(3) its distal part : becomes divided by a spiral septum into pulmonary trunk & ascending aorta (see page 10).

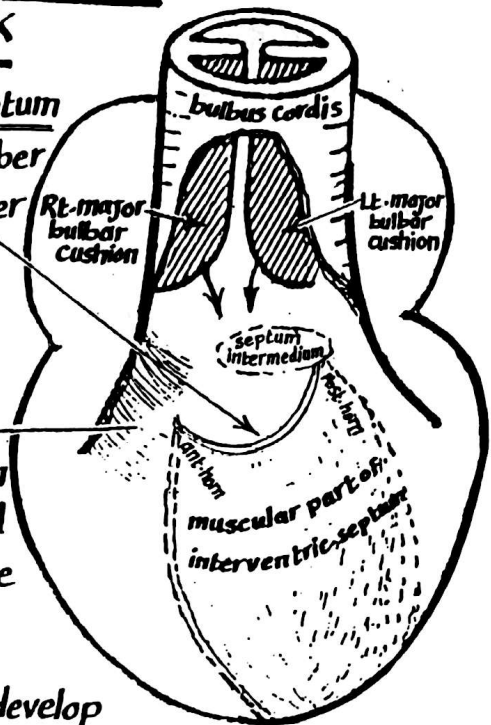


## 4-Septum formation in the bulboventricular region & development of the 2 ventricles and the aorta & pulmonary trunk

10

(1) At first, the muscular part of the interventricular septum develops from the floor of the bulbo-ventricular chamber as a crescentic ridge having free concave upper border with ant. & post. horns.

(2) the muscular part of the interventricular septum grows cranially till the ant-horn fuses with the ventral surface of the root of the bulbus cordis while the post. horn fuses with the septum intermedium. The cavity of the common ventricle is thus subdivided incompletely into Rt & Lt. ventricles which communicate with each other as well as with the bulbus cordis.



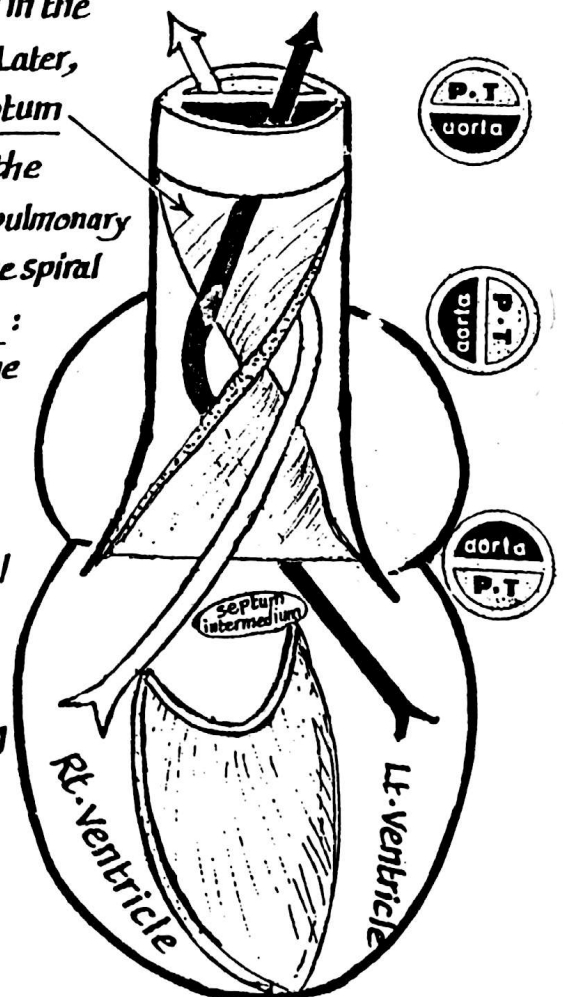
(3) 2 ridges called the Rt. & Lt. major bulbar cushions develop inside the distal part of the bulbus cordis & descend in the direction of the ventricles following a spiral course. Later, they fuse together forming aortico-pulmonary septum.

(4) the distal part of the bulbus becomes divided by the aortico-pulmonary septum into ascending aorta & pulmonary trunk which are twisted on each other (due to the spiral course of the septum) acquiring the following relation:

- (a) most distally, the pulmonary trunk lies dorsal to the ascending aorta.
- (b) in the middle: the pulmonary trunk lies to the left of the ascending aorta.
- (c) most proximally: the pulmonary trunk lies ventral to the aorta.

(5) the membranous part of the interventricular septum develops late to fill the gap still connecting the 2 ventricles. It is formed by proliferation of all cushions which surround the gap i.e:

- (a) the Rt. & Lt. major bulbar cushions.
- (b) the ant. & post. atrioventricular cushions.



# DEVELOPMENT OF THE AORTIC AND PULMONARY VALVES

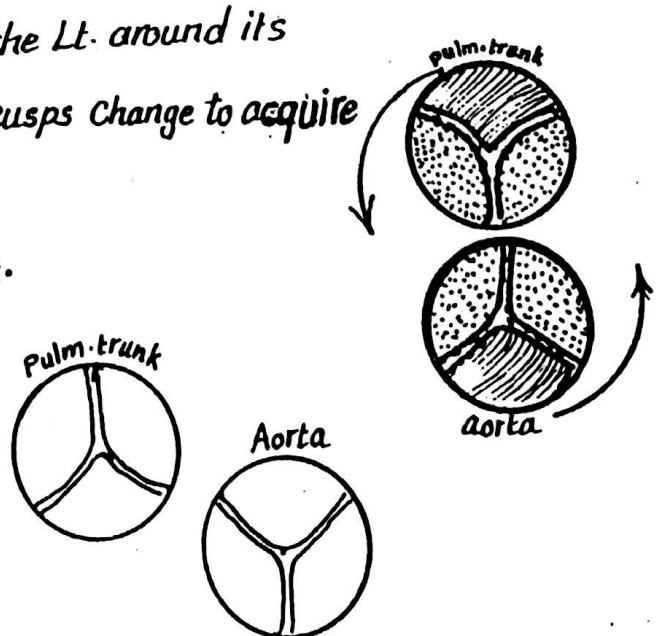
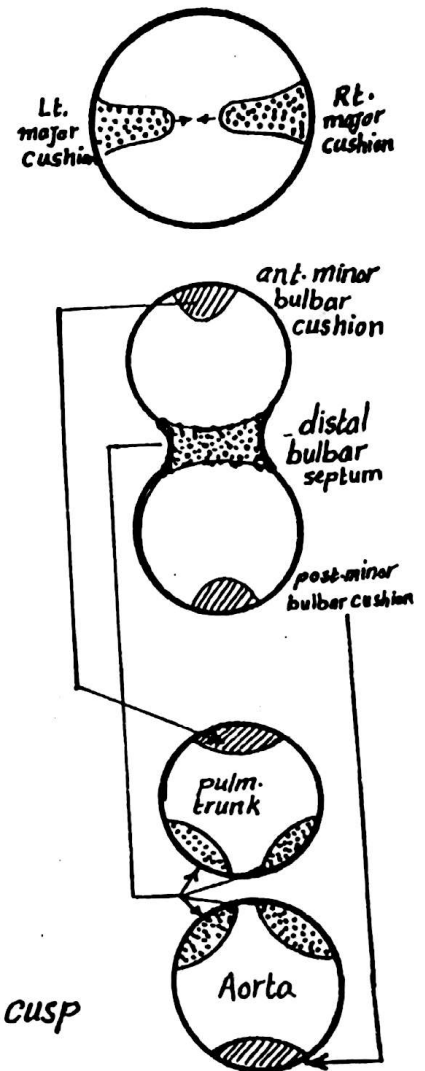
11

\* They develop at the junction between the bulbus cordis & the truncus arteriosus from the following sources :

- (1) The Rt. & Lt. major bulbar cushions
- (2) The ant. & post. minor bulbar cushions.

\* The development proceeds as follows :

- (1) The Rt. & Lt. major bulbar cushions unite in the region of the valves to form the distal bulbar septum
- (2) Two accessory ridges called the ant. & post. minor bulbar cushions arise in the ant. & post. walls of the common orifice of the bulbus cordis at a plane perpendicular to the bulbar septum.
- (3) The ant. minor bulbar ridge forms the ant. cusp of the pulmonary valve
- (4) The Rt. & Lt. major bulbar cushions give rise to :
  - (a) the 2 posterolateral pulmonary cusps
  - (b) the 2 anterolateral aortic cusps
- (5) The post. minor bulbar cushion forms the post. aortic cusp
- (6) As a result of rotation of the heart to the Lt. around its longitudinal axis the position of the cusps change to acquire the adult position :
  - the pulmonary cusps become one post. and 2 anterolateral.
  - the aortic cusps become one anterior & 2 posterolateral



# Endocardial Cushions

12

\* **Definition:** they are mesodermal thickenings of the endocardial tissue which fuse together leading to septum formation at various sites of the primitive heart.

\* **Types:**

## (A) Ant. & post. endocardial cushions:

- **Site:** they appear in the ant. & post. walls of the atrioventricular canal

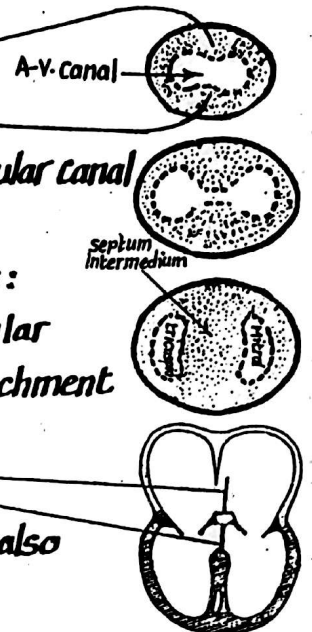
- **Fate & derivatives:**

they fuse together giving rise to the following derivatives:

(1) Septum intermedium which divides the common atrio-ventricular canal into Rt. (tricuspid) & Lt. (mitral) canals & gives attachment to the interatrial septum.

(2) a part of the membranous interventricular septum.

(3) the cusps of the mitral & tricuspid valves (which are formed also by other minor cushions in the atrioventricular canal).



## (B) Rt. & Lt. major bulbar cushions (ridges):

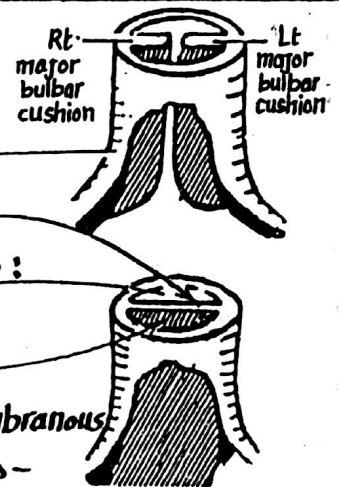
- **Site:** they develop in the Rt. & Lt. walls of the proximal part of the bulbus cordis

- **Fate:** they unite together forming the bulbar septum which divides the proximal part of the bulbus into:

(1) aortic vestibule (dorsally & to the left)

(2) infundibulum (ventrally & to the right)

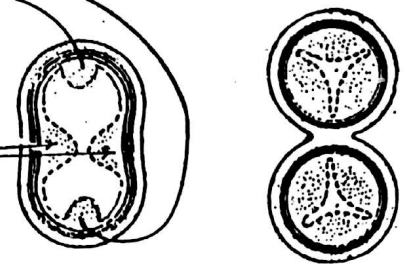
**N.B.** the bulbar septum is continuous caudally with the membranous part of interventricular septum & cranially with the aortico-pulmonary septum in the truncus arteriosus (distal part of the bulbus).



## (C) Ant. & Post. minor bulbar cushions:

- **Site:** they develop in the ant. & post. walls of the distal part of the bulbus cordis


- **Fate:** they share with the Rt. & Lt. major bulbar cushions in the formation of the aortic & pulmonary semilunar cusps.






# Anomalies of the interventricular Septum


13



(1) a defect in the membranous part is frequently seen.



(2) a defect in the membranous as well as the muscular part occasionally occurs.

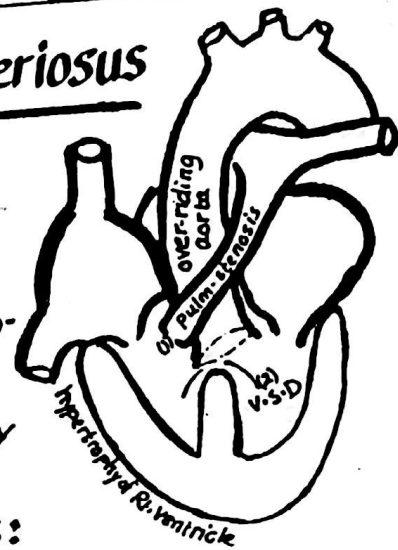


(3) the whole inter-ventricular septum may be absent.

## Anomalies of the truncus arteriosus

### (1) Fallot's tetralogy:

- \* it is the Commonest anomaly of the heart.
- \* it is due to displacement of the aortico-pulmonary septum anteriorly leading to unequal division of the Conus (narrow origin of pulmonary trunk).



\* Fallot's tetralogy consists of 4 anomalies:

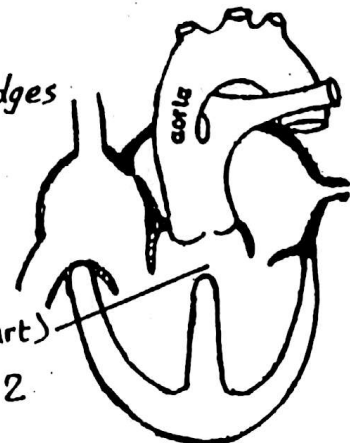
- (1) pulmonary stenosis.
- (2) hypertrophy of the Rt. ventricle (Caused by the pulmonary stenosis).
- (3) ventricular septal defect.
- (4) Over-riding aorta i.e the mouth of the aorta overlies the ventricular septal defect & receives blood from both Rt. & Lt. ventricles.

N.B: Eiseminger's Complex: is similar to Fallot but without pulmonary stenosis.

### (2) Persistent truncus arteriosus:

- \* This is due to failure of fusion of the 2 spiral ridges (bulbar cushions) to form the aortico-pulmonary septum.

- \* This anomaly is usually accompanied by
- (1) ventricular septal defect (in the membranous part)
  - (2) over-riding aorta (receives blood from the 2 ventricles).



## 14

- 
- Diagram of the heart showing the pulmonary trunk and aorta. The pulmonary trunk is labeled "pulm. trunk" and the aorta is labeled "aorta". The right ventricle is labeled "R" and the left ventricle is labeled "L". Arrows indicate the flow of blood from the right ventricle into the pulmonary trunk and from the left ventricle into the aorta.

**(1) pulmonary stenosis:**

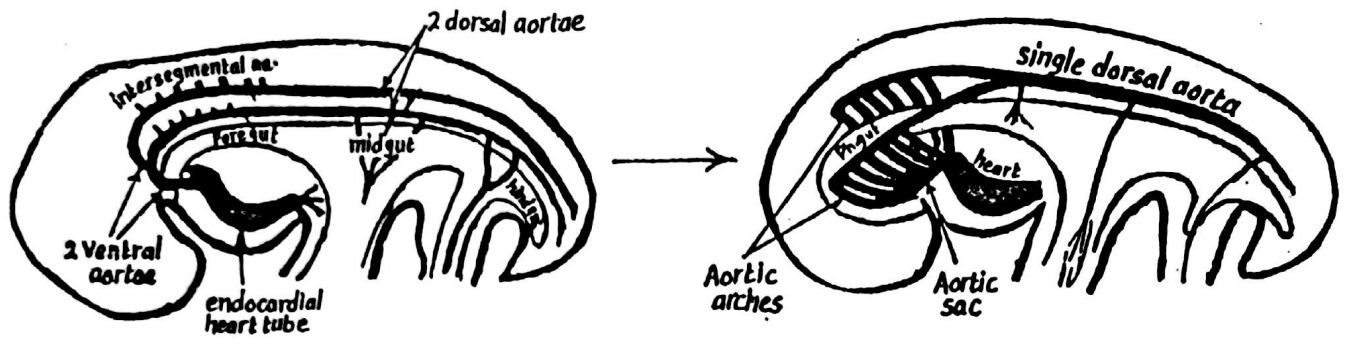
- 
- A schematic diagram of the heart and major vessels. The aorta is shown at the top, and the pulmonary trunk is below it. Arrows point to the openings of these vessels, with labels 'aortic stenosis' and 'pulmon-stenosis' respectively. The diagram illustrates the anatomical locations of these two types of stenosis.

- \* due to fusion of the cusps of the aortic valve
- \* the ductus arteriosus remains patent & delivers blood to the aorta.

**(1) Dextro cardia:**

- 
- An anatomical illustration of the human respiratory and circulatory systems. It shows a frontal view of the thoracic cavity. The heart is centrally located, with its major vessels (aorta and pulmonary artery) extending upwards. On either side of the heart are the lungs, which are depicted with a textured, lobulated surface. The right lung is on the left side of the image, and the left lung is on the right side. The trachea and bronchi are visible as branching structures within the lungs.

# DEVELOPMENT OF THE ARTERIES 15

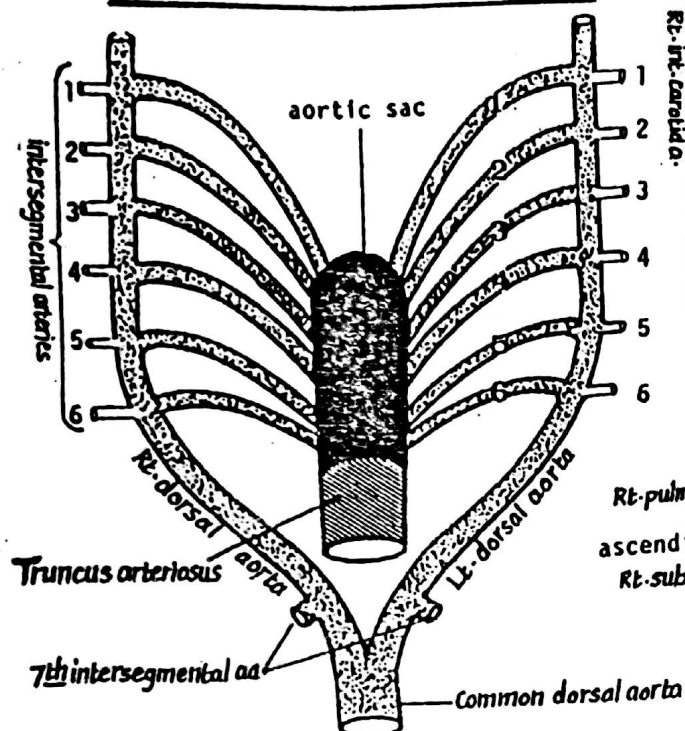


- \* The vascular system appears in the middle of the 3<sup>rd</sup> week from fixed primitive blood vessel-forming angiogenetic cells (mesodermal in origin).
- \* the first arteries to appear in the embryo are the Rt. & Lt. primitive aortae. which appear as a continuation of the 2 endocardial heart tubes.
- \* the 2 primitive aortae curve dorsally in the 1<sup>st</sup> pharyngeal arch, around the ant part of the foregut then continue dorsally as the 2 dorsal aortae.
- \* The aortic sac: the 2 primitive (ventral) aortae fuse together close to the heart forming a dilated channel called the aortic sac lying ventral to the pharynx & is continuous caudally with the truncus arteriosus. The aortic sac is formed of a stem & 2 horns (Rt. & Lt.).
- \* The 2 dorsal aortae: pass caudally dorsal to the primitive gut. They fuse together all through forming single dorsal aorta except their cranial parts which remain separate & are continuous with the 2 ventral aortae via the 1<sup>st</sup> aortic arch arteries.

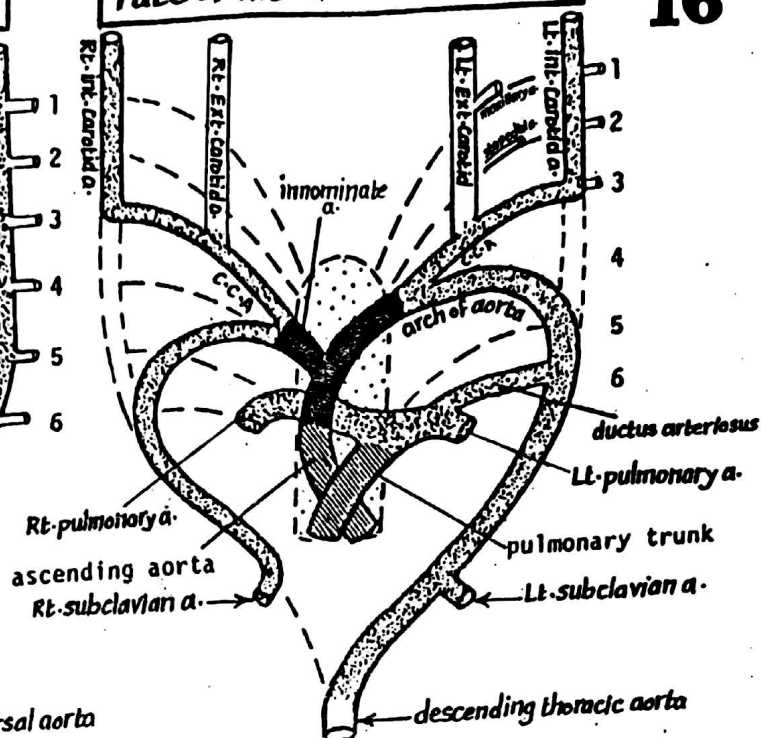
## AORTIC ARCHES

- \* Definition: they are 6 pairs of arteries which connect the aortic sac ventrally with the 2 dorsal aortae dorsally. They run in the pharyngeal arches along the side wall of the pharynx.
- \* Development (formation):
  - as the pharyngeal arches begin to develop, the aortic sac sends a pair of branches to each pharyngeal arch.
  - each branch (called aortic arch artery) leaves the aortic sac, curves around the pharynx (inside the corresponding pharyngeal arch) to end in the dorsal aorta.
  - there are 6 pairs of aortic arches (for the 6 pharyngeal arches) but they are never present at the same time, as by the time the 3<sup>rd</sup> pair develops the 1<sup>st</sup> pair disappears.

### Formation of the aortic arches



### Fate of the aortic arches



## FATE OF THE AORTIC ARCHES

The aortic arches undergo changes in number & arrangement as follows:

Aortic arch	Right	Left
1 <sup>st</sup> .	disappears except for a small part which forms the Maxillary a.	
2 <sup>nd</sup> .	disappears except for a small part which forms the Stapedial a. (a branch of post-auricular a.).	
3 <sup>rd</sup> .	forms the Common carotid a. & the proximal part of the internal carotid a. The external carotid a. arises as a bud from the 3 <sup>rd</sup> arch	
4 <sup>th</sup>	forms the proximal part of the Rt. subclavian a.	forms the proximal part of the arch of aorta.
5 <sup>th</sup>	disappears completely & very early on both sides leaving no trace.	
6 <sup>th</sup>	each 6 <sup>th</sup> arch divides into ventral (med.) & dorsal (lat.) segments - the ventral segment forms the Rt. pulmonary a. which enters the Rt. lung bud. - the dorsal segment disappears (loses its connection with the dorsal aorta).	- the ventral segment forms the Lt. pulmonary a. which enters the Lt. lung bud - the dorsal segment persists during the intrauterine life forming the ductus arteriosus which forms a connection between the Lt. pulm. a. & the arch of aorta.

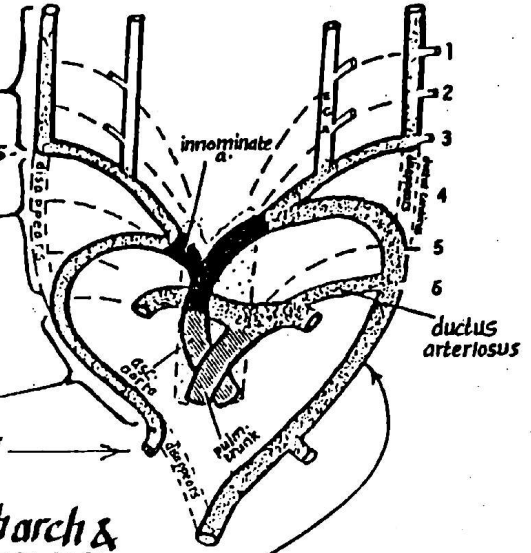


### \* Fate of the aortic sac:

- (1) the Rt. horn: form the brachiocephalic (innominate) a. which is continuous with the Rt. Common Carotid (of the Rt. 3<sup>rd</sup> aortic arch) & with the stem of the Rt. subclavian a. (of the 4<sup>th</sup> Rt. aortic arch).
- (2) the Stem + the Lt. horn: form the proximal part of the arch of the aorta.

### \* Fate of the Rt. & Lt. dorsal aortae:

- (1) the segment cranial to the 3<sup>rd</sup> aortic arch: forms the distal part of the internal carotid a. on both sides.
- (2) the segment between the 3<sup>rd</sup> & 4<sup>th</sup> aortic arches (called ductus caroticus): disappears on both sides.
- (3) the segment of the Rt. dorsal aorta between the 4<sup>th</sup> arch & 7<sup>th</sup> arch: forms part of the Rt. subclavian a. which continues as the 7<sup>th</sup> Rt. intersegmental artery.
- (4) the segment of the Lt. dorsal aorta between the 4<sup>th</sup> arch & 7<sup>th</sup> Lt. intersegmental a.: forms the distal part of arch of aorta.
- (5) the segment of the Rt. dorsal aorta between the Rt. 7<sup>th</sup> intersegmental a. & the common dorsal aorta: degenerates completely.



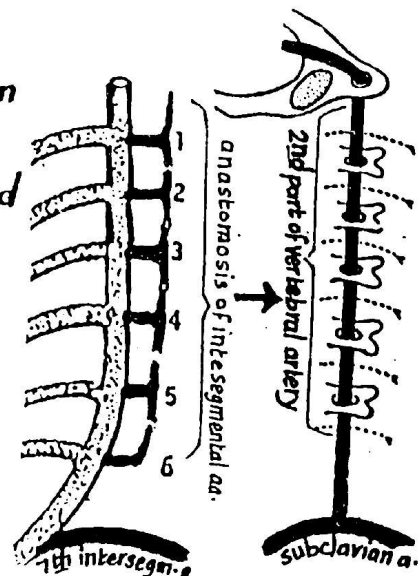
### Development of the arch of the aorta

- the arch of aorta develops from 4 sources as follows:

- (a) its proximal part (proximal to the origin of the innominate a.): arises from the stem of aortic sac.
- (b) its middle part (between the innominate & Lt. C. Carotid a.): arises from the Lt. horn.
- (c) its distal part (distal to the Lt. Common Carotid a.) arises from 2 sources:
  - (1) the Lt. 4<sup>th</sup> aortic arch
  - (2) the lower part of the Lt. dorsal aorta down to the 7<sup>th</sup> intersegmental artery.

### \* Fate of Cervical intersegmental arteries:

- there are 7 cervical intersegmental arteries arising from each of the Rt. & Lt. dorsal aortae.
- the upper 6 intersegmental arteries become connected by vertical anastomoses which will give rise to:
    - (a) 2<sup>nd</sup> part of the vertebral a.
    - (b) the deep cervical a.
    - (c) the sup. intercostal a.
  - the 7<sup>th</sup> intersegmental a. itself forms the subclavian a. while the upper 6 intersegmental arteries degenerate.



## \* Relations of the recurrent laryngeal nn. to the aortic arches: 18

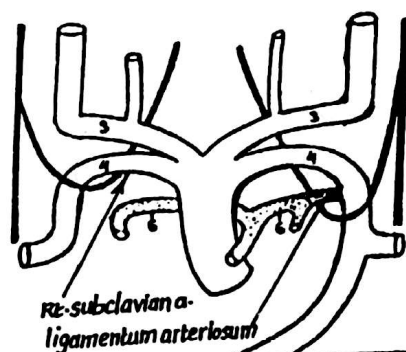
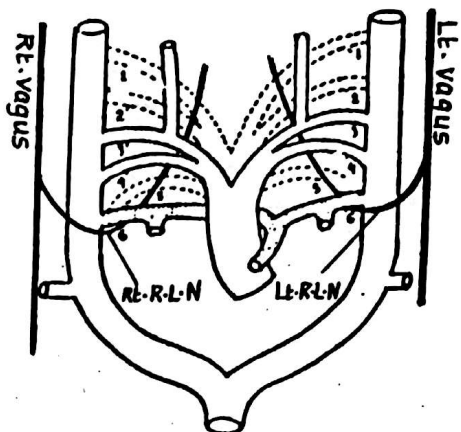
• In the early development, the Rt. & Lt. vagi descend lat. to the pharynx, being separated from it by the aortic arches.

• Each vagus gives a recurrent laryngeal branch which hooks around the dorsal part of the 6th arch to reach the developing larynx.

• As development proceeds the following occur :

(A) on the Rt. side: the dorsal part of the 6th arch + the 5th arch degenerate, leaving the Rt. recurrent laryngeal n. hooking around the 4th Rt. aortic arch which forms the Rt. subclavian a.

(B) on the Lt. side: the Lt. recurrent laryngeal n. remains hooking around the dorsal part of the Lt. 6th arch which does not disappear but forms the ductus arteriosus (obliterates after birth forming ligamentum arteriosum which is overlapped by the arch of aorta)



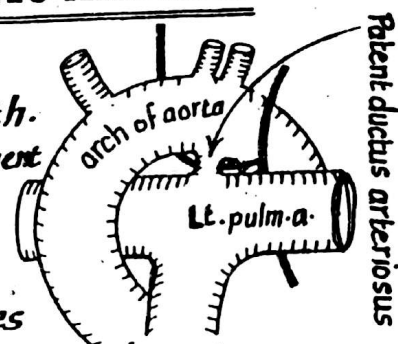
## CONGENITAL ANOMALIES OF THE AORTIC ARCHES

### (1) Patent ductus arteriosus:

\* Normally, the ductus arteriosus closes shortly after birth.

\* Failure of closure of the ductus arteriosus leads to establishment of a communication between the Lt. pulmonary a. & the arch of aorta.

\* Patent ductus arteriosus is one of the commonest anomalies of the great vessels. It leads to progressive hypertrophy of the Lt. side of the heart.



### (2) Coarctation of the aorta:

\* It is Congenital narrowing of the aorta distal to the origin of the Lt. subclavian a. It may be one of the 2 following types:

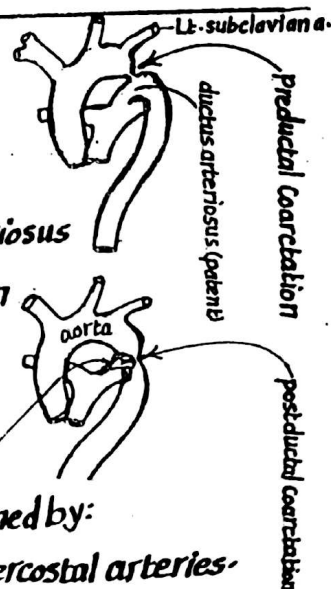
(a) Preductal type: narrowing of aorta above the level of ductus arteriosus in this case, the ductus remains patent to maintain the circulation to the lower part of the body.

(b) Postductal type: narrowing of the aorta distal to the level of the ductus which will close to form the ligamentum arteriosum.

In this type, the circulation to the lower part of the body is maintained by:

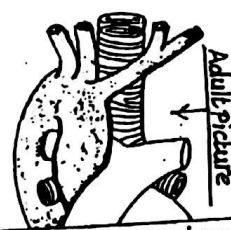

(1) anastomosis between the arteries around the scapula & the post-intercostal arteries.

(2) " " " sup. epigastric & inf. epigastric arteries.



### (3) Right-sided aortic arch:

this anomaly results from the persistence of the distal part of the right dorsal aorta & degeneration of the distal part of Lt. dorsal aorta.



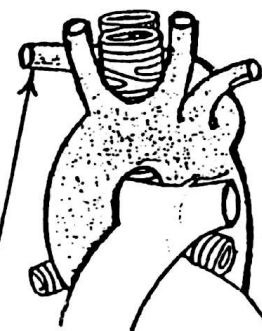

### (4) Double aortic arch:

- this anomaly results from the persistence of the distal parts of both Rt. & Lt. dorsal aortae
- it leads to the formation of a vascular ring around the trachea & oesophagus causing difficulty in breathing & swallowing.



### (5) Abnormal Rt. subclavian artery:

- it is due to degeneration of the Rt. 4th aortic arch & the adjoining part of the Rt. dorsal aorta down to the origin of the Rt. 7th intersegmental a.
- the abnormal Rt. subclavian a. is represented by the Rt. 7th intersegmental a. + distal part of the Rt. dorsal aorta which is found in the adult arising from the descending thoracic aorta & passing to the Rt. side behind the oesophagus.



## THE COMMON DORSAL AORTA

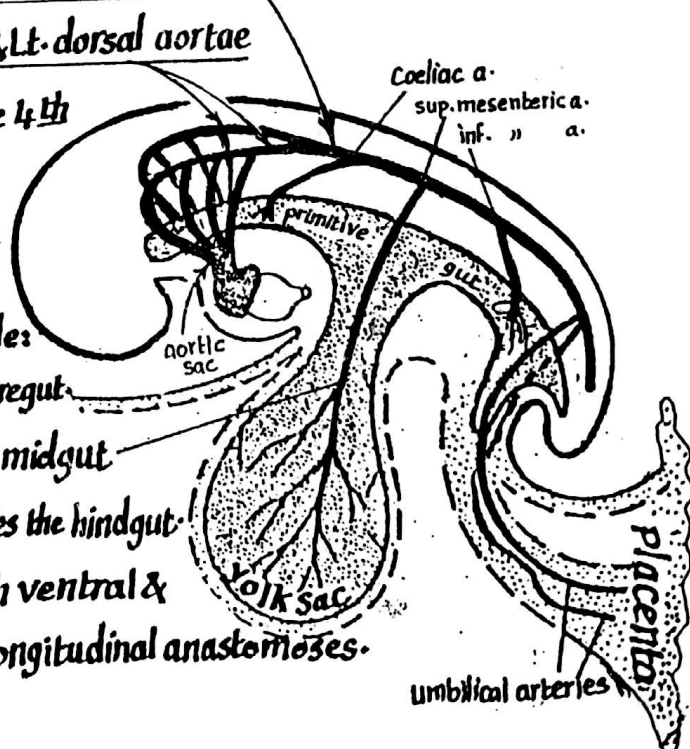
\* Formation: it is formed by the union of the Rt. & Lt. dorsal aortae in the region extending from the 4<sup>th</sup> thoracic to the 4<sup>th</sup> lumbar segment (somite).

### \* Branches:

(i) Ventral splanchnic arteries: arise from the ventral aspect to supply the primitive gut & include:

- Coeliac a.: the most cranial br. & supplies the foregut.
- Sup. mesenteric a.: the middle br. & supplies the midgut.
- Inf. mesenteric a.: the most caudal br. & supplies the hindgut.

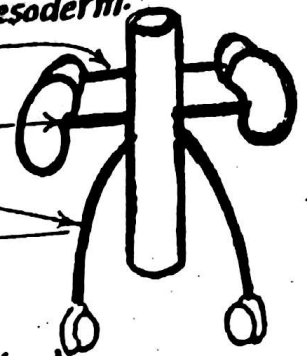
N.B.: these arteries anastomose together both ventral & dorsal to the gut forming ventral & dorsal longitudinal anastomoses.



## (2) Lateral Splanchnic branches:

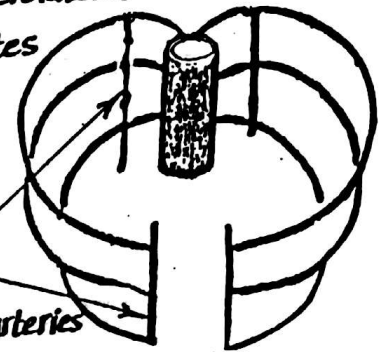
20

- These are paired branches (Rt. & Lt.) which arise from the lat. aspect of dorsal aorta to supply structures arising from the intermediate mesoderm.
- They include : (1) middle suprarenal arteries
- (2) renal arteries
- (3) gonadal arteries (testicular or ovarian)



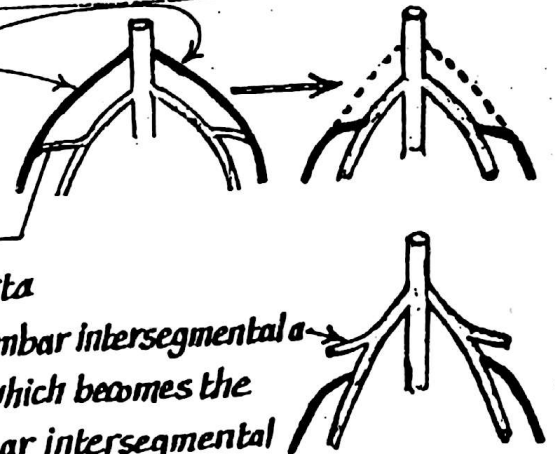
## (3) Intersegmental (Somatic) arteries:

- these are paired branches (Rt. & Lt.) which arise from the posterolateral aspect of the dorsal aorta & pass laterally between the somites
- they are represented in the adult by the post-intercostal, subcostal & the lumbar arteries.
- they anastomose together both ventrally & dorsally producing ventral & dorsal longitudinal anastomoses
- their ventral anastomoses produces in the adult the following arteries  
(1) internal thoracic a. (2) sup. epigastric a. (3) inf. epigastric a.



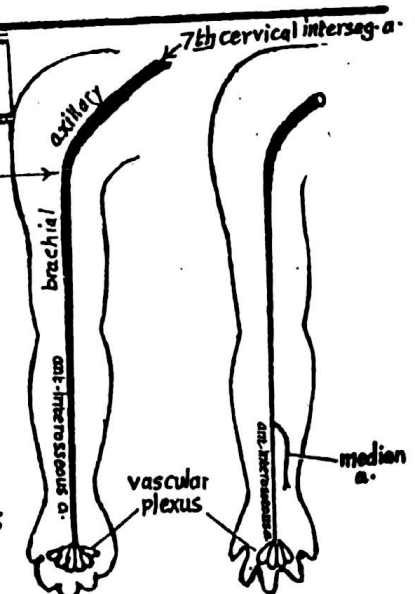
## (4) Umbilical arteries (Rt. & Lt.)

- At first, they arise from the dorsal aorta.
- then they become connected to the 5th lumbar intersegmental artery by an anastomosis
- then they lose their connection to the dorsal aorta
- the external iliac artery arises as a br. of the 5th lumbar intersegmental a. leaving the umbilical a. attached to its distal part which becomes the internal iliac a. The proximal part of the 5th Lumbar intersegmental a. now becomes the common iliac artery.



## DEVELOPMENT OF ARTERIES OF U.L

- \* The arteries of the U.L develop from an axial artery which runs in the axis of the limb.
- \* it arises from the 7th intersegmental a. & proceeds distally as the subclavian, axillary, brachial & ant. interosseous aa.
- \* it ends in the hand by forming a deep vascular plexus which will become later the deep palmar arch.
- \* a median a. arises as a br. from the ant. interosseous a. & runs along the median n. to communicate with the capillary plexus in the hand replacing the ant. interosseous a. which regresses from the palmar plexus.



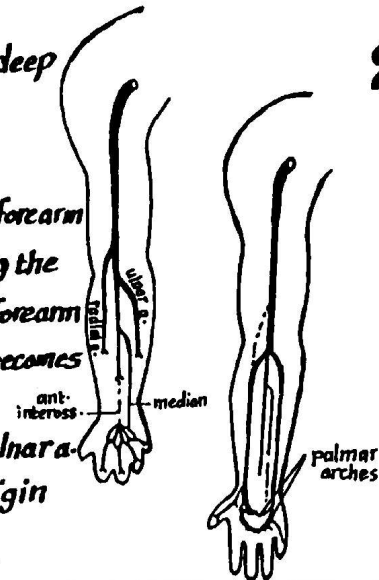


\* the palmar capillary plexus differentiates into superficial & deep palmar arches.

\* the axial a. gives off 2 branches in the elbow region:

- (1) ulnar a. which runs distally along the ulnar border of the forearm & becomes connected to the superficial palmar arch replacing the median a. which regresses upwards forming a minute a. in the forearm
- (2) radial a. which runs along the radial side of the forearm & becomes connected to the deep palmar arch.

**N.B.:** the radial a. arises at first at a higher level than the ulnar a. then it anastomoses with the brachial a. opposite the origin of the ulnar a. then its proximal part degenerates.



### DEVELOPMENT OF ARTERIES OF THE L.L

\* The axial a. of the L.L. is the continuation of the 5<sup>th</sup> lumbar intersegmental a. It follows the sciatic n., hence it is called sciatic artery.

\* It descends through the gluteal region, back of thigh & back of leg (deep to the popliteus m. & calf muscles)

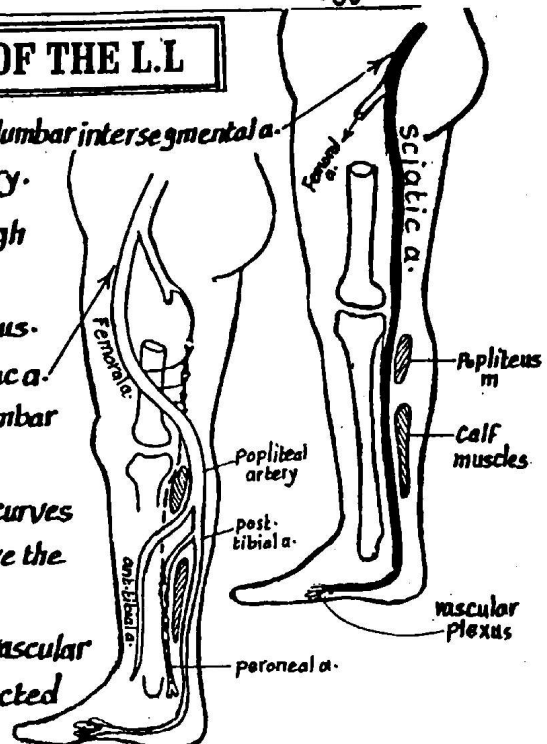
\* It ends in the sole of the foot by forming a vascular plexus.

\* the femoral a. develops later as a continuation of ext. iliac a. (which arises as a new br. of the proximal part of the 5<sup>th</sup> lumbar intersegmental a. which becomes the common iliac a.)

\* the femoral a. descends in the front of the thigh then curves backwards to join the axial a. in the popliteal fossa above the popliteus m., forming the popliteal a.

\* the ant. & post. tibial arteries develop from local vascular plexuses in the front & back of the leg and become connected to the popliteal a.

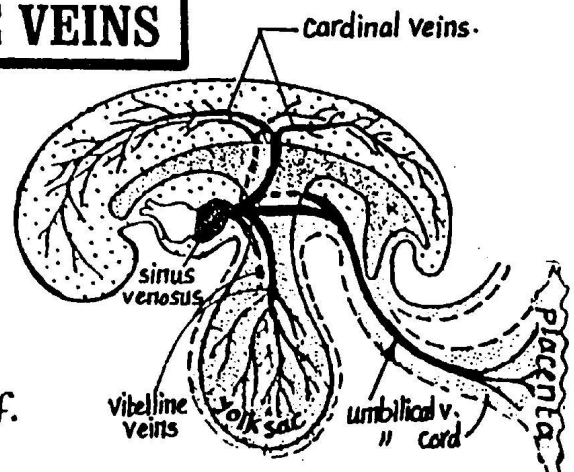
\* the axial a. then degenerates, its remnants in the adult L.L. are represented by:  
(1) inf. gluteal a. (2) Companion a. of sciatic n. (3) longitudinal anastomosis in the back of thigh  
(4) peroneal a. in the back of leg.



### DEVELOPMENT OF THE VEINS

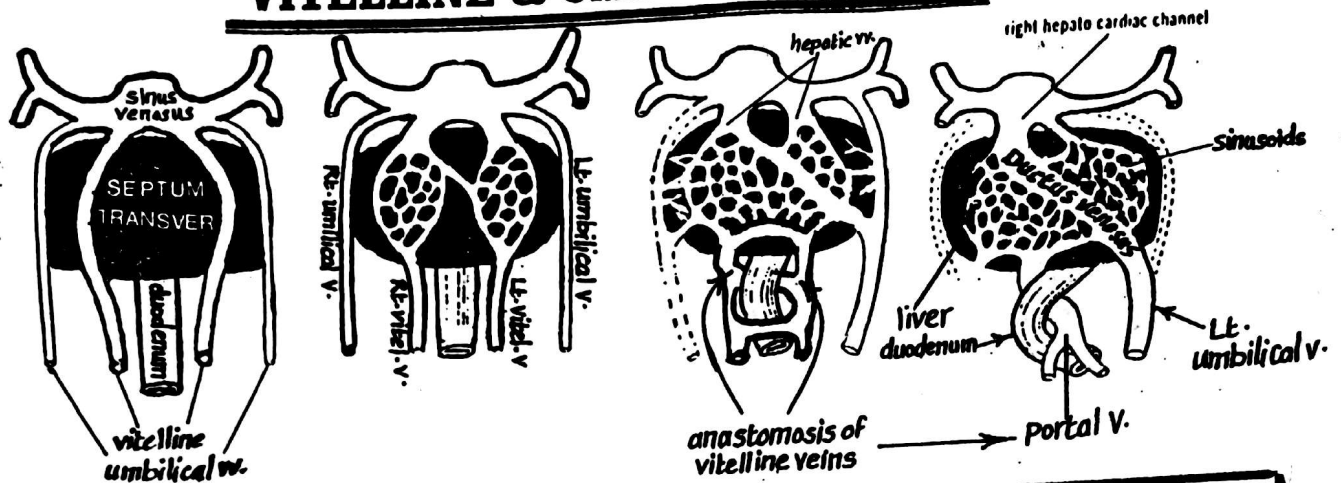
\* There are 3 types of veins in the embryo:

- (1) Vitelline veins: drain the blood from the yolk sac
- (2) Umbilical veins: carry oxygenated blood from the placenta & pass as one umbilical v. in the umbilical cord which duplicates on entering the body of the embryo forming Rt. & Lt. umbilical veins.
- (3) Cardinal veins: drain the body of the embryo itself.



# VITELLINE & UMBILICAL VEINS

22

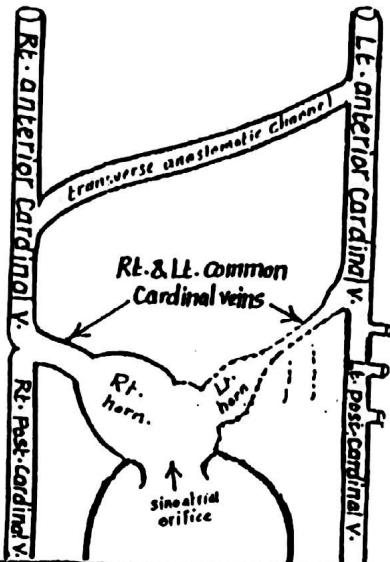
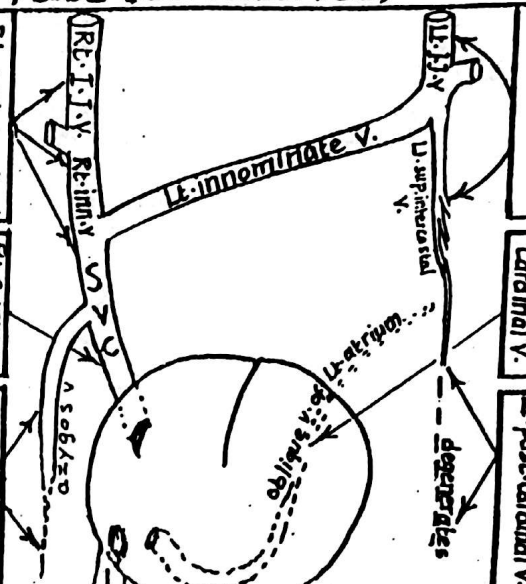



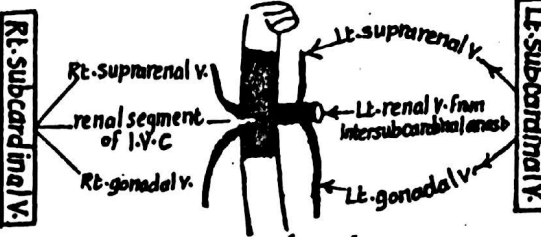
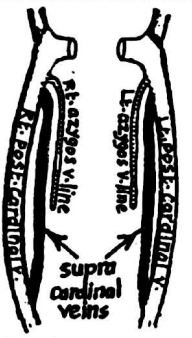
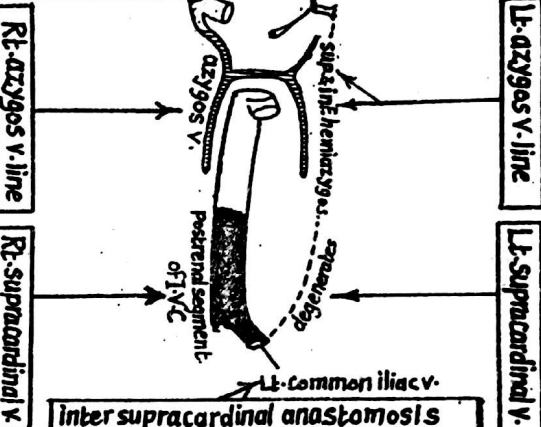
	Vitelline veins (Rt. & Lt.)	Umbilical veins (Rt. & Lt.)
<b>origin:</b>	<u>arise</u> from network of capillaries in the mesoderm of the wall of the <u>yolk sac</u> & <u>enter</u> the body of the embryo via the yolk sac stalk.	<u>arise</u> from the <u>placenta</u> as one vein which <u>enters</u> the body via the umbilical cord then duplicates forming Rt. & Lt. umbilical veins.
<b>Course:</b>	they pass cranially, one on each side of the <u>duodenum</u> , then traverse the <u>septum transversum</u> to end in the Rt. & Lt. horns of the <u>sinus venosus</u> .	they pass cranially traversing the peripheral parts of the <u>septum transversum</u> to end in the Rt. & Lt. horns of the <u>sinus venosus</u> .
<b>Fate:</b> (derivatives)	<p>(a) <u>the caudal parts</u> : become connected by 3 anastomotic channels (2 ventral &amp; one dorsal to the duodenum) forming a figure of 8 which undergoes partial degeneration giving S-shaped channel which forms the <u>portal Vein</u>.</p> <p>(b) <u>the middle parts</u> (inside the septum transversum) : become invaded by the liver cell cords &amp; broken down into <u>hepatic sinusoids</u>.</p> <p>(c) <u>the cranial parts</u> : the cranial part of the <u>Lt. vitelline v.</u> disappears while that of the <u>Rt. v.</u> persists forming :</p> <p>(1) the Rt. &amp; Lt. <u>hepatic veins</u>.</p> <p>(2) the <u>hepatocardiac channel</u> which will form the terminal part of the I.V.C.</p>	<p>1- the <u>Rt. umbilical v.</u> disappears completely</p> <p>2- the <u>Lt. v.</u> persists as the only vessel carrying oxygenated blood from the placenta &amp; has the following fate:</p> <p>(a) its <u>caudal part</u> runs in the free margin of the falciform ligament.</p> <p>(b) its middle part (inside the septum transversum) is invaded by the liver cell cords &amp; becomes transformed into <u>hepatic sinusoids</u>. As development proceeds, some sinusoids enlarge forming a large channel called <u>ductus venosus</u> which connects the proximal part of the Lt. umbilical v. with the <u>hepato-cardiac channel</u> of the Rt. vitelline v.</p> <p>(c) its part cranial to the septum transversum disappears.</p>

\* These are symmetrical longitudinal venous channels which appear in successive stages inside the body of the embryo to convey its venous blood. They will give rise to the main systemic veins of the adult.

\* The cardinal veins include:

- (1) Anterior cardinal vv. (2) posterior Cardinal vv. (3) common cardinal veins  
(4) subcardinal veins (5) Supracardinal veins (6) Azygos line veins

CARDINAL VEINS	Development	Fate (derivatives)
(1) Rt & Lt Anterior Cardinal Veins		
(2) Rt & Lt Posterior Cardinal Veins	<p>* They descend from the base of the head to open into the sinus venosus, draining the H &amp; N. as well as the upper limbs</p> <p>* the Rt. &amp; Lt. ant. cardinal vv. become connected by a transverse anastomotic channel which shifts blood from the left side to the right side.</p>	<p>(A) <u>the Lt. ant. cardinal vein:</u></p> <p>(1) its upper part forms the Lt. I.J.V.</p> <p>(2) its lower part forms Lt. sup. intercostal v.</p> <p>(B) <u>the Rt. ant. cardinal v.:</u> forms</p> <p>(1) the Rt. I.J.V. (2) Rt. innominate vein</p> <p>(2) the upper part of the S.V.C.</p> <p>(C) <u>the transverse anastomosis:</u></p> <p>forms the Lt. innominate v.</p>
(3) Rt & Lt Common Cardinal Veins	<p>* They develop as the veins of the mesonephros &amp; lie dorsal to them. They also drain the lower limbs &amp; caudal part of the trunk &amp; ascend to join the common cardinal v.</p> <p>* the Rt. &amp; Lt. post. cardinal veins are linked to each other in the region of the pelvis by iliac anastomosis</p>	<p>A- <u>the left post. cardinal v.:</u></p> <p>degenerates except its cranial part which forms the distal part of the Lt. sup. intercostal v.</p> <p>B- <u>the Rt. post. cardinal v.:</u> degenerates except its cranial part which forms the upper part of the azygos v.</p> <p>C- <u>the iliac anastomosis:</u> forms the most caudal part of the I.V.C.</p>
	<p>each common cardinal v. is formed by the union of the corresponding ant. &amp; post. cardinal vv. &amp; opens into the lat. horn of the sinus venosus.</p>	<p>(A) <u>the Lt. common cardinal v.:</u> shrinks &amp; forms the oblique v. of Lt. atrium.</p> <p>(B) <u>Rt. common cardinal v.:</u> forms the lower part of the S.V.C.</p>

Vein	Development	Fate (derivatives):
<p>4-Rt &amp; Lt. <u>Subcardinal Veins</u></p>	 <p>* They <u>appear</u> after the post-cardinal vv. &amp; lie ventromedial to the mesonephroi</p> <p>* the Rt. &amp; Lt. subcardinal vv. <u>anastomose</u> together in front of the aorta forming the inter-subcardinal anastomosis.</p>	 <p>(1) The <u>Lt. subcardinal V.</u> gives:</p> <p>(a) Lt. suprarenal v. (from its upper part).</p> <p>(b) Lt. gonadal v. (from its lower part).</p> <p>(2) the <u>Intersubcardinal anastomosis</u> forms the Lt. renal v.</p> <p>(3) the <u>Rt. Subcardinal V.</u> gives: the renal segment of I.V.C. + Rt. gonadal &amp; Rt. suprarenal veins.</p>
<p>5-Rt &amp; Lt. <u>Supracardinal Veins</u></p>	 <p>* They are the <u>last venous system</u> to appear</p> <p>* they <u>lie dorsilateral</u> to the aorta &amp; lat. to the sympathetic chains.</p> <p>* each vein is <u>linked</u> both cranially &amp; caudally to the corresponding postcardinal v. In order to replace it.</p> <p>* the Rt. &amp; Lt. veins <u>anastomose</u> together forming intersupracardinal anastomosis &amp; also anastomose with the subcardinal veins forming sub-supracardinal anastomosis.</p>	 <p>(1) the <u>Lt. Supracardinal V.</u>: degenerates</p> <p>(2) the <u>Rt. Supracardinal V.</u>: forms the postrenal segment of the I.V.C. which is the major part of the I.V.C. lying below the level of the renal veins.</p> <p>(3) the <u>intersupracardinal anastomosis</u> forms the Lt. common iliac vein.</p>
<p>Rt. &amp; Lt. <u>Azygos line</u> veins</p>	<p>* They <u>lie</u> dorsilateral to the aorta but medial to sympathetic chain.</p> <p>* Each azygos venous line is <u>connected</u> cranially with the corresponding post-cardinal v.</p>	<p>(1) The <u>Lt. azygos venous line</u>: forms the sup. &amp; inf. hemiazygos vv.</p> <p>(2) the <u>Rt. azygos venous line</u>: gives most of the azygos v. (except its upper part which is derived from the Rt. post-cardinal v.).</p>

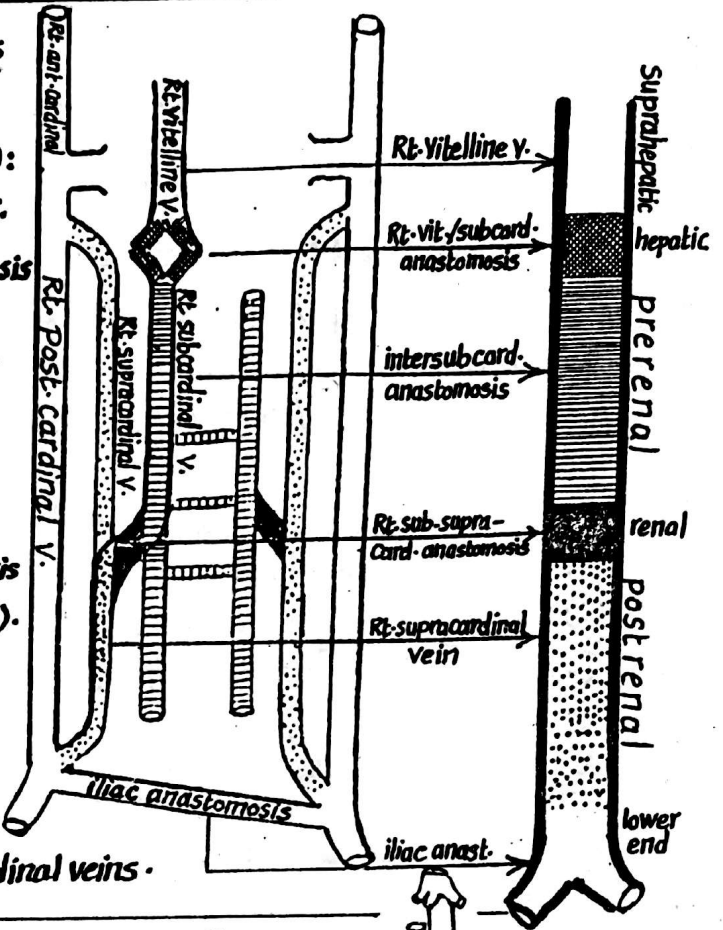


# DEVELOPMENT OF THE I.V.C

25

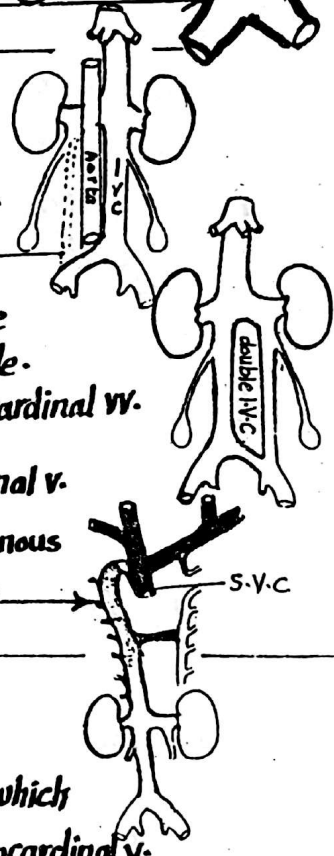
\* The I.V.C is formed of the following 6 parts  
(From above downwards):

- (1) Suprahepatic segment (uppermost part):  
formed by the proximal part of the Rt. vitelline V.
- (2) Hepatic segment: formed by the anastomosis  
between the Rt. vitelline V. & Rt. subcardinal V.
- (3) Prerenal segment (above the kidneys):  
formed by intersubcardinal anastomosis &  
part of the Rt. subcardinal V.
- (4) Renal Segment (opposite the kidneys):  
formed by the Rt. sub-supracardinal anastomosis  
(anast. between Rt. subcardinal & Rt. supracardinal vv.).
- (5) Post-renal segment (below the kidneys):  
it is the main part of the I.V.C. & is formed by  
the Rt. supracardinal V.
- (6) the lowest segment (beginning) of I.V.C  
formed of the iliac anastomosis of the post-cardinal veins.



## ANOMALIES OF THE I.V.C

- (1) Lt. I.V.C.: the I.V.C lies on the Lt. side of the abdominal aorta instead of being on its Rt. side. It results from persistence of the Lt. supracardinal V. & disappearance of the Rt. supracardinal V.
- (2) Double I.V.C: in this case, there is a left-sided I.V.C below the level of the renal veins, in addition to the normal I.V.C. on the Rt. side. This condition results from the persistence of both the Lt. & Rt. supracardinal vv.
- (3) Absent I.V.C: It is a rare condition in which the Rt. subcardinal V. fails to join the hepato cardiac channel (of the Rt. vitelline V.) The venous blood of the lower part of the body reach the heart via the azygos vein.



## Development of the renal veins

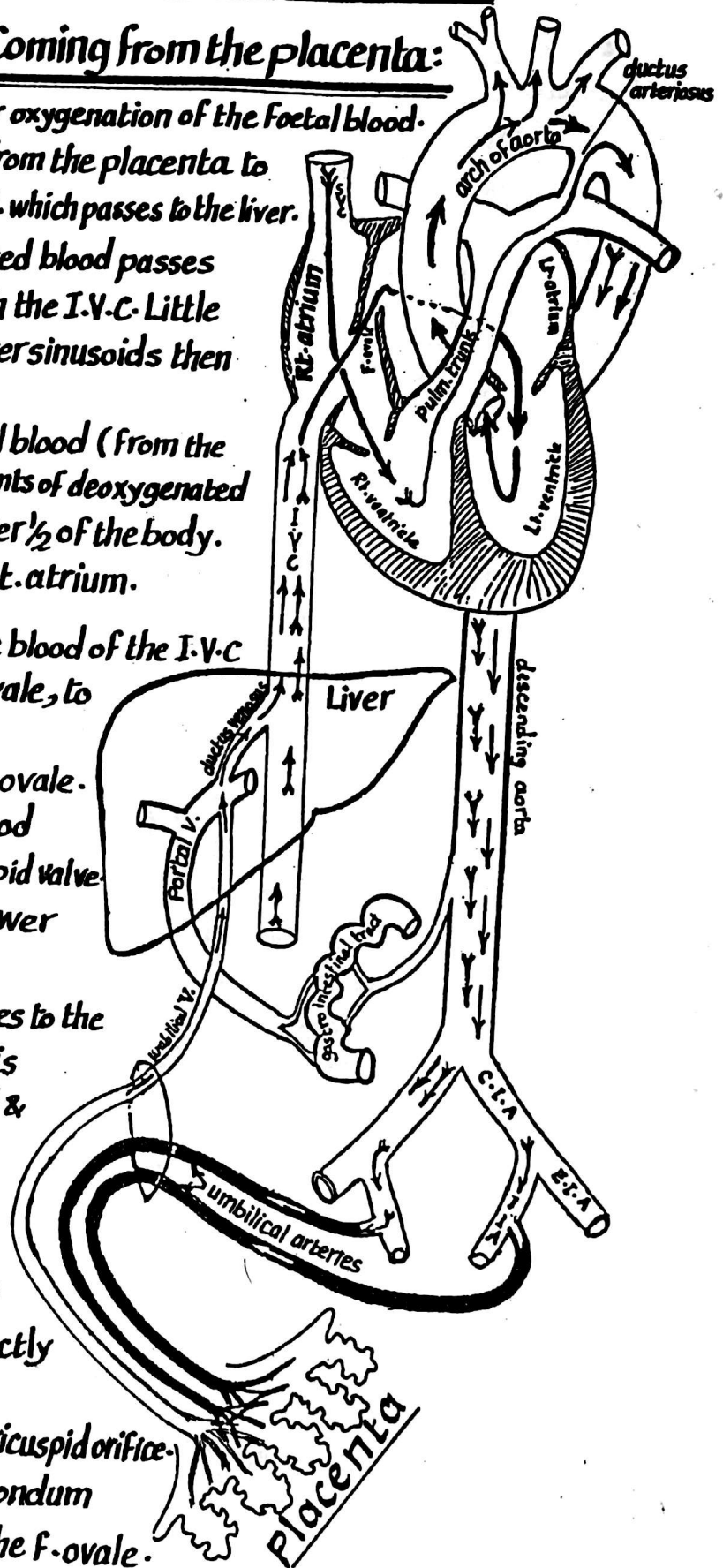
- (1) the Rt. renal V.: is formed totally by the Rt. metanephric V. which emerges from the metanephros to join the Rt. subcardinal V.
- (2) the Lt. renal V.: it is longer than the Rt. renal V. & has a double origin:
  - (a) from the Lt. metanephric V. which joins the Lt. subcardinal V.
  - (b) from the intersubcardinal anastomosis between the 2 subcardinal vv.

# FOETAL CIRCULATION

26

## I- The oxygenated blood Coming from the placenta:

- \* The placenta acts as a lung for oxygenation of the foetal blood.
- \* the oxygenated blood is carried from the placenta to the foetus via the Lt. umbilical V. which passes to the liver.
- \* In the liver: most of the oxygenated blood passes through the ductus venosus to reach the I.V.C. Little amount of blood passes through the liver sinusoids then reach the I.V.C.
- \* the I.V.C.: carries the oxygenated blood (from the placenta) which mixes with little amounts of deoxygenated blood reaching the I.V.C from the lower  $\frac{1}{2}$  of the body. The I.V.C finally opens into the Rt. atrium.
- \* In the Rt. atrium: most of the blood of the I.V.C is directed, through the foramen ovale, to the Lt. atrium because:
  - (1) the opening of the I.V.C. faces the F. ovale.
  - (2) the valve of the I.V.C directs the blood towards F. ovale & away from tricuspid valve.
  - (3) the pressure in the Lt. atrium is lower than that of the Rt. atrium.
- \* From the Lt. atrium the blood passes to the Lt. ventricle and the aorta where it is distributed mainly to the heart, head & neck and upper limbs.



## II- The deoxygenated blood

- Carried by the S.V.C: reaches the Rt. atrium where it passes directly to the Rt. ventricle because:
  - (1) the opening of the S.V.C faces the tricuspid orifice.
  - (2) the lower border of the septum secundum prevents the blood from entering the F. ovale.
- \* On reaching the Rt. ventricle, the deoxygenated blood passes to the pulm. trunk

★ From the pulmonary trunk : little amount of blood goes to the lungs (collapsed), while the majority of blood escapes through the ductus arteriosus to reach the distal part of the arch of aorta where it mixes with the oxygenated blood. 27

**III- The Dorsal aorta :** carries partially oxygenated blood which is distributed to the abdomen , lower limbs & finally passes through the 2 umbilical arteries to the placenta to be oxygenated & returned to the embryo again via the umbilical V.

## CHANGES IN THE CIRCULATION AFTER BIRTH

### (A)-Immediate changes:

#### (1) Establishment of pulmonary circulation:

- immediately after birth, the lungs expand due to the anoxia resulting from stoppage of the placental blood flow (stimulates the respiratory centres of the foetus).
- the expansion of the lungs creates negative intra-thoracic pressure leading to suction of blood into the lungs & establishment of the pulmonary circulation.

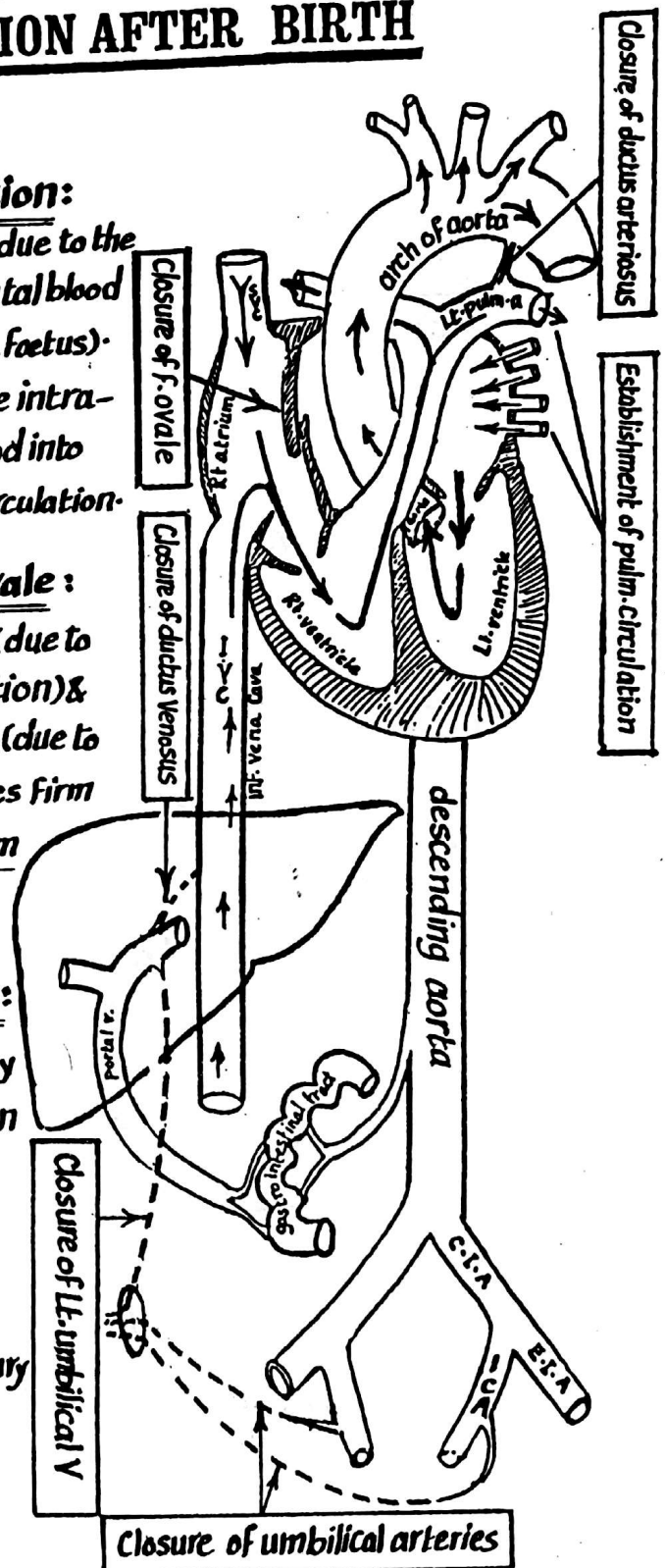
#### (2) Functional closure of the foramen ovale :

the increased pressure inside the Lt-atrium (due to the establishment of the pulmonary circulation) & the decreased pressure inside the Rt-atrium (due to stoppage of the placental blood flow) causes firm apposition of the septum primum to the septum secundum leading to closure of F. ovale.

#### (3) Functional closure of ductus arteriosus:

the ductus arteriosus becomes functionally closed immediately after birth by contraction of its thick muscular wall leading to :

- (a) cutting short the shunt between the Lt- pulmonary a. & the arch of aorta
- (b) passage of all the blood of the pulmonary trunk to the lungs.



## **(B) Late Fibrotic changes:**

28

during the first year of post natal life some of the vessels become fibrosed & change into ligaments as follows :

- (1) the Lt. umbilical V.: becomes the ligamentum teres of the liver which extends from the umbilicus to the Lt. branch of the portal V.
- (2) Ductus venosus: becomes the ligamentum venosum of the liver which extends from the Lt. branch of the portal V. to the I.V.C.
- (3) Ductus arteriosus: becomes the ligamentum arteriosum connecting the Lt. pulmonary a. to the arch of aorta.
- (4) the umbilical arteries: become the lateral umbilical ligaments. The proximal part of each umbilical a., however, remains patent & gives the sup. vesical artery which supplies the urinary bladder.

---

## **General remarks about the foetal Circulation :**

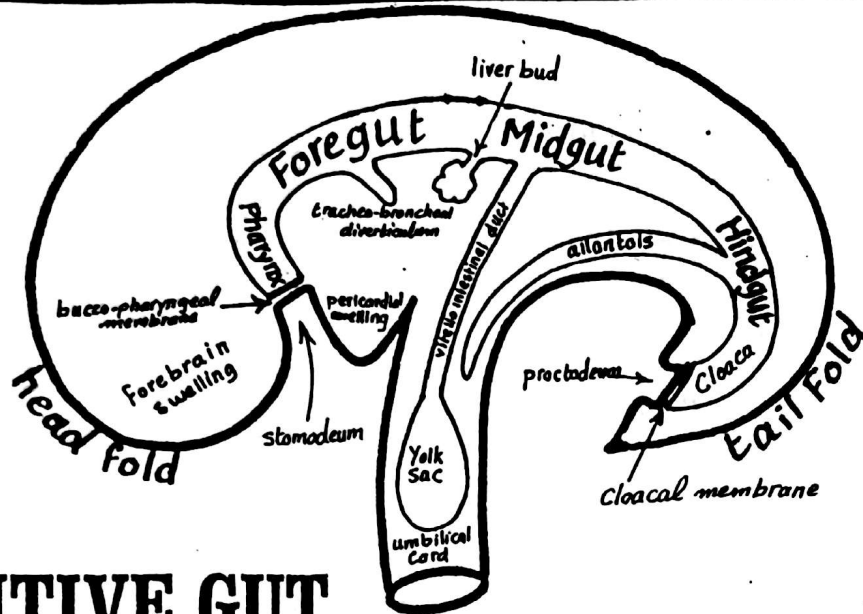
(A) The tissues of the foetus receive partially oxygenated blood due to mixing of the oxygenated & deoxygenated blood in the following sites:

- (1) in the liver: where mixing occurs between the blood of the Lt-umbilical v. (oxygenated) & that of the portal v. (deoxygenated).
- (2) in the I.V.C: the blood of the ductus venosus mixes with the venous blood returning from the lower parts of the body of the foetus
- (3) In the Lt. atrium: the blood reaching it mixes with little amounts of venous blood returning from the lung buds.
- (4) In the dorsal aorta: its blood mixes with the deoxygenated blood passing through the ductus arteriosus.

(B) As a result of the structural changes occurring after birth, the heart & the circulation become divided functionally into 2 halves :

- (1) Rt. half: receiving & pumping deoxygenated blood only.
- (2) Lt. half:    "       "       "       oxygenated blood only.





## \* PRIMITIVE GUT

- \* At the end of the 3rd week, folding of the embryonic disc occurs
- \* As a result of formation of the 2 lat. folds, the endodermal roof of the yolk sac becomes included inside the embryo forming the Primitive gut.
- \* As a result of the antero-posterior folding, the head fold is formed enclosing the cephalic part of the primitive gut which is now called the Foregut. Also the tail fold is formed enclosing the caudal part of the primitive gut which is called hindgut
- \* the Intervening part between the foregut & the hindgut is called the Midgut which communicates with the yolk sac via the vitello-intestinal duct.
- \* the junction between foregut & midgut is called the anterior intestinal Portal.
- \* " " " midgut & hindgut " " " posterior intestinal portal.
- \* The whole primitive gut is formed of a lining of endoderm & a covering of splanchnic (visceral) mesoderm with the exception of the 2 ends of the digestive tube.

(a) mouth cavity ant. to buccopharyngeal membrane (called stomodaeum) } both are ectodermal in origin  
 (b) lower 1/2 of anal canal below anal membrane (called proctodaeum) }

## FOREGUT

### Anterior part (pharyngeal gut).

extends from the buccopharyngeal memb. to the tracheo-bronchial diverticulum & gives:

- (1) the post. part of the mouth cavity
- (2) the pharynx
- (3) the respiratory tract

### Posterior part

extends from the tracheo-bronchial diverticulum till the origin of the liver bud (ant. intestinal portal)

and gives:

- (1) the oesophagus, stomach & upper 1/2 of duodenum
- (2) the liver & gall bladder
- (3) " pancreas

\* The mouth cavity develops from 2 sources:

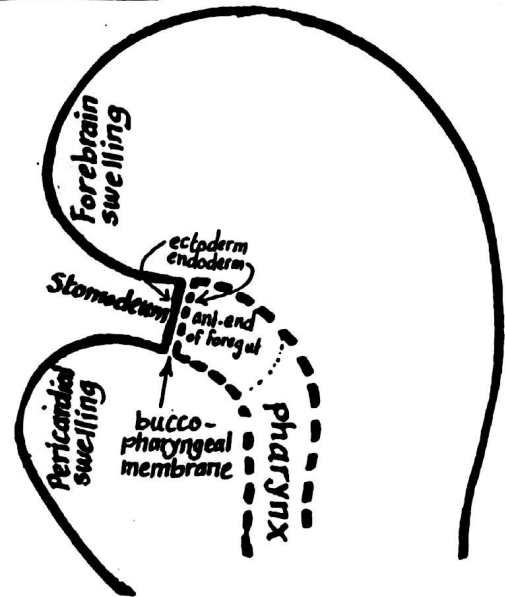
(1) the Stomodeum which is a depression lined with ectoderm resulting from the enlargement of the pericardium & the fore brain & is enclosed between the 2.

(2) the floor of the ant. end of foregut which is lined by endoderm.

\* the ectodermal stomodeum & the endodermal ant. end of foregut are separated by the buccopharyngeal membrane (bilaminar).

\* At the end of the 3rd week the buccopharyngeal membrane ruptures & the primitive mouth cavity is formed by the 2 components.

\* the demarcation line between ectoderm & endoderm is a line just behind the gums.



## SALIVARY GLANDS

### 1--PAROTID



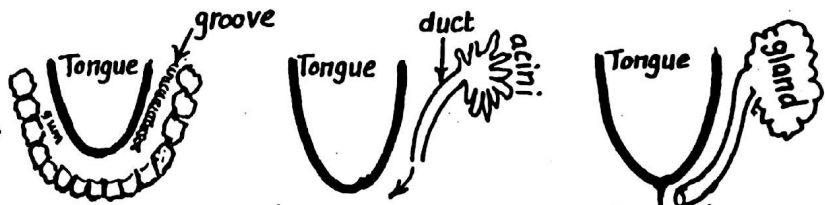
\* a groove appears behind the angle of the mouth (lined by buccal epithelium)

\* the groove then closes to form the parotid duct which extends backwards

\* the blind distal end branches repeatedly & canalizes to form the acini of the gland

\* the duct recedes from the angle of mouth to open in the vestibule of mouth opposite the upper 2nd molar tooth.

### 2-- SUBMANDIBULAR




(1) a groove appears between the tongue and the gums (alveolo-lingual groove)

(2) the groove then closes to form the submandibular duct

(3) the distal (post.) end of the duct grows backwards along the floor of mouth, branches repeatedly & canalizes to form the acini of the gland

(4) the ant. end of the duct proceeds forwards to open close to the frenulum of the tongue

### 3-- SUBLINGUAL GLAND



(1) it arises as small buds developing from the alveolo-lingual groove.

(2) these buds attain a common sheath and appear as one gland having several openings into the floor of the mouth.

# PHARYNGEAL (BRANCHIAL) APPARATUS 31

- \* **Definition:** the pharyngeal arches are 6 curved cylindrical mesodermal thickenings on each side of the primitive pharynx. Each arch forms a swelling on the outer surface of the embryo & a swelling on the wall of the primitive pharynx internally.

## \* **Formation:**

- they are produced by the proliferation of the mesoderm of the lat. wall of the pharynx forming 6 arched thickenings.
- each arch consists of
  - (1) an outer ectodermal covering
  - (2) an inner endodermal lining
  - (3) a mesodermal core between the two
- the arches are separated from each other externally by 5 grooves called pharyngeal clefts
- " " " " " " " internally by 4 grooves called pharyngeal pouches
- each ectodermal cleft is separated from the corresponding endodermal pouch by a thin layer of mesoderm.

## \* **Time of appearance:**

- the ph. arches start to appear on the outer surface of the embryo at the age of 4-5 weeks, the cranial arches precede the caudal ones & are more prominent than them

- \* **Fate:** after the 5th week, they become transformed into bones, cartilages, ligaments, muscles & vessels of the head & neck.

## \* **Shape (description) of the arches:**

### 1 - the 1st arch : (called the mandibular arch):

the longest & most prominent arch. It divides externally into 2 processes: a short maxillary process & a long mandibular process.

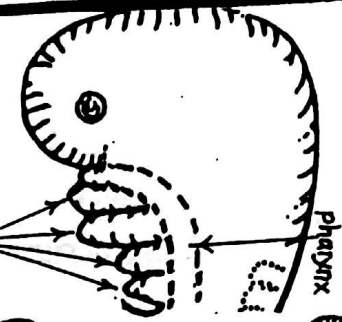
### 2 - the 2nd arch (called the hyoid arch): less prominent than the 1st.

N.B: the ventral ends of the 1st & 2nd arches reach the middle line of the floor of the pharynx.

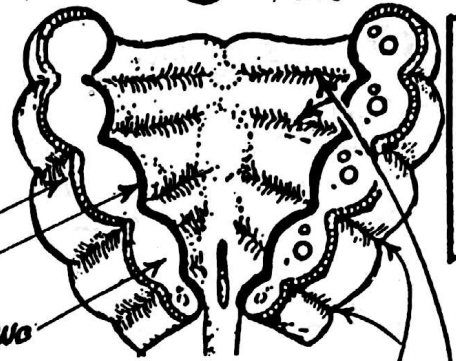
### (3) & (4) - the 3rd & 4th arches: are not prominent (lie in a depression on the surface) & their ventral ends do not reach the middle line of the floor of pharynx but meet in a median swelling called the hypobranchial eminence.

### (5) the 5th arch: is rudimentary & disappears early.

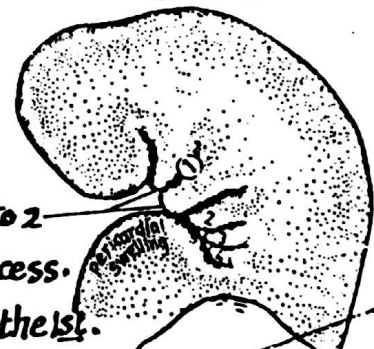
### (6) the 6th arch: is the most caudal & is not prominent on the surface.



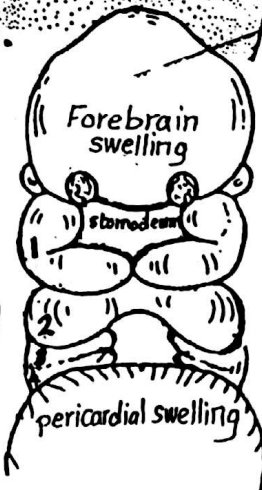
Lateral View



Coronal section



Lateral view



Front view

## \* Basic Structure of the pharyngeal arch:

the mesodermal core of the pharyngeal arch differentiates into the following components :

### (1) Skeletal element (arch cartilage):

- a cartilagenous bar develops from the mesodermal core of the arch & is surrounded by a pericondrial sheath.
- the cartilagenous bar will differentiate into certain cartilages, ligaments & bones in the head & neck.

### (2) Muscular element:

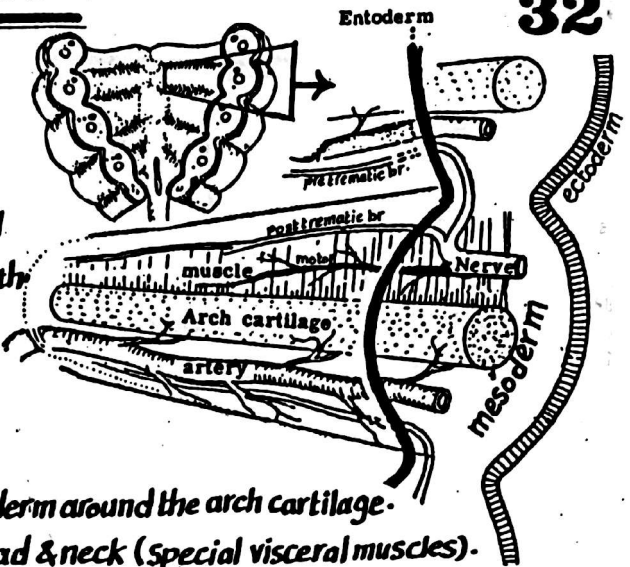
- a striated muscle mass develops from the mesoderm around the arch cartilage.
- it will differentiate into certain muscles in the head & neck (special visceral muscles).

### (3) Vascular element: an aortic arch artery develops in each pharyngeal arch & becomes connected to the aortic sac ventrally & to the dorsal aorta dorsally.

### (4) Nervous element: represented by a mixed (motor & sensory) cranial nerve which arises from the lat.-aspect of the hindbrain & grows into the arch dividing into :

- (a) motor br.: supplies the striated muscle mass (special visceral muscles) of its own arch.
- (b) post-trematic sensory br.: runs with the motor n. & supplies its own arch.
- (c) pre-trematic sensory br.: ascends to supply the preceding arch

thus each arch contains its own nerve (motor & post-trematic) + the pre-trematic br. of the nerve of the succeeding (next) arch.



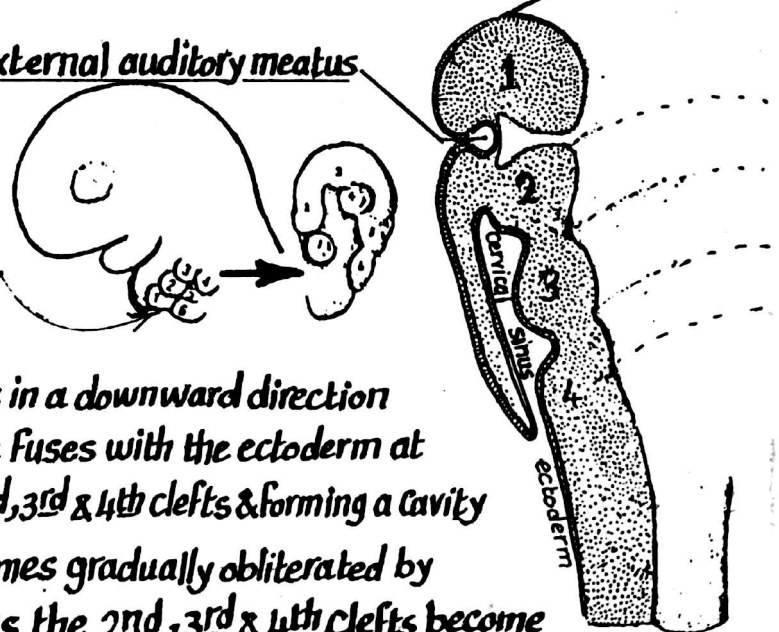
## 1--DERIVITIVES OF THE PHARYNGEAL CLEFTS (ECTODERM)

### (1)- First cleft:

- a- its dorsal part deepens to form the external auditory meatus & the outer layer of the ear drum.
- b- the auricle of the ear develops by the fusion of 6 thickenings situated around the entrance of the 1st cleft.

### (2) 2nd, 3rd & 4th clefts:

- the mesoderm of the 2nd arch grows in a downward direction pushing the overlying ectoderm till it fuses with the ectoderm at the root of the neck thus covering the 2nd, 3rd & 4th clefts & forming a cavity called the Cervical Sinus which becomes gradually obliterated by apposition & fusion of its walls. Thus the 2nd, 3rd & 4th clefts become buried & do not give rise to any structure.





## 2- DERIVATIVES OF THE PHARYNGEAL POUCHES ( ENDODERM) **33**

### (1) First pouch:

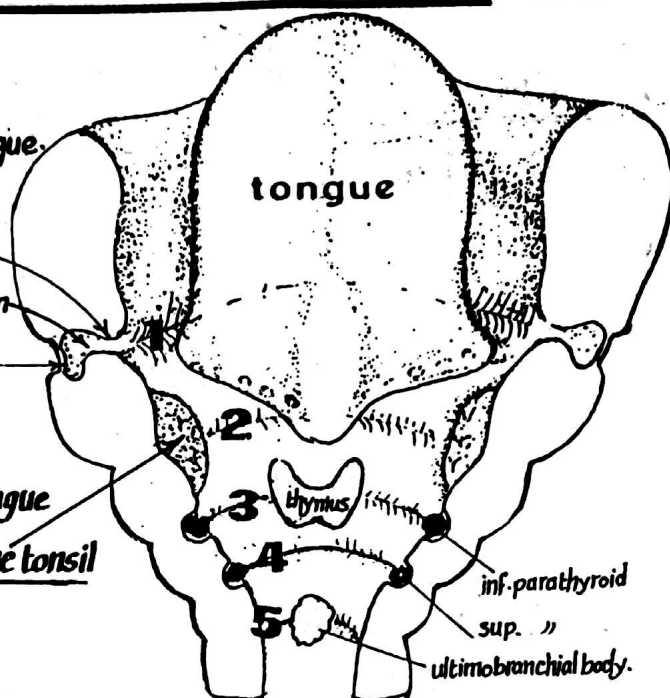
(a) ventral part : obliterated by the developing tongue.

(b) dorsal part : forms the tubotympanic recess

which gives: (1) the pharyngo-tympanic tube

(2) the middle ear cavity & mastoid antrum

(3) the inner layer of the ear drum



### (2) Second pouch:

(a) ventral part : obliterated by the developing tongue

(b) dorsal part : gives the primordium of the palatine tonsil

### (3) third pouch:

(a) ventral part : form the thymus gland (will migrate caudally to enter the thorax).

(b) dorsal part : form the inferior parathyroid gland (will migrate caudally to lie below the sup. parathyroid gland).

### (4) fourth pouch:

(a) its ventral part : gives small contribution to (1) the sides of the thyroid gland.  
(2) the thymus gland.

(b) its dorsal part : gives the superior parathyroid gland.

### (5) fifth pouch:

gives rise to a small cellular mass called the ultimobranchial body which probably becomes incorporated into the thyroid gland forming its para-follicular cells.

## Development of the palatine tonsil

it arises from the endoderm of the dorsal part of the 2nd pouch as follows:

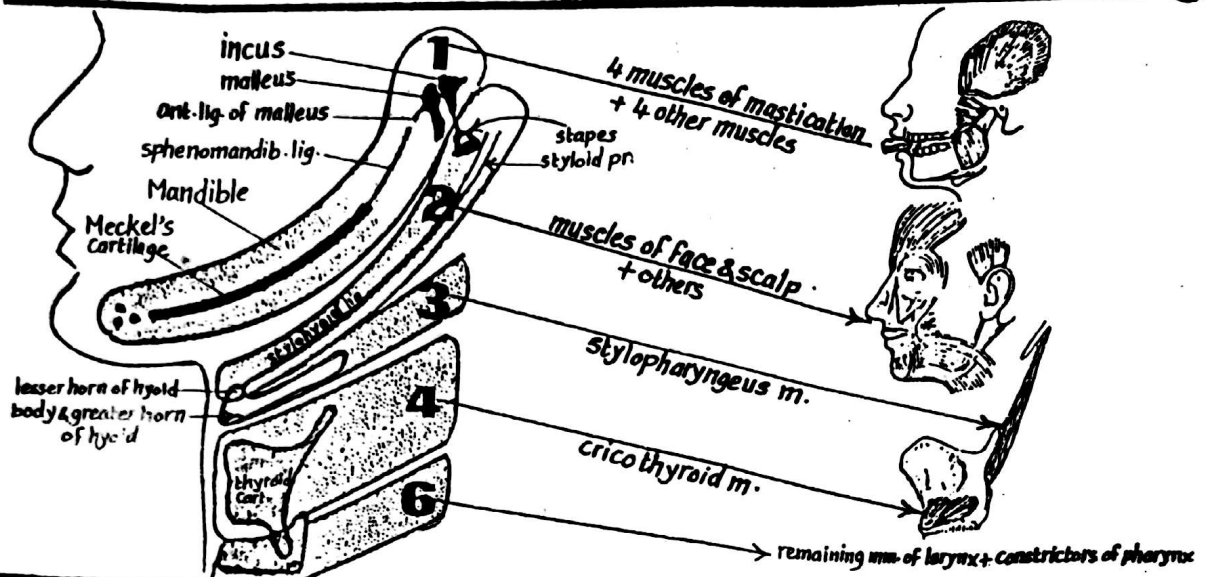
(1) the endoderm proliferates forming a number of buds

(2) the buds become canalized to form crypts.

(3) the tonsil become invaded by lymphocytes.

(4) the remnant of the cavity of the 2nd pouch forms the intratonsillar cleft.

### 3- DERIVATIVES OF THE PHARYNGEAL ARCHES (MESODERM) 34



Arch	Skeletal derivatives	Muscular derivatives	Nerve
<b>1<sup>st</sup> arch</b> (mandibular arch)	<u>Meckel's Cartilage</u> : differentiates into the following structures: - <u>dorsally</u> : it gives incus & malleus - <u>middle part</u> : sphenomandibular lig. & ant. lig. of malleus - <u>ventrally</u> : gives the most ant. part of the body of mandible. The rest of mandible develops by membranous ossification around the meckel's cartilage	(A) <u>the 4 muscles of mastication</u> : (1) temporalis (2) masseter (3) lat. pterygoid (4) med. pterygoid. (B) <u>4 other muscles</u> : (1) mylohyoid (2) ant. belly of digastric (3) tensor palati (4) tensor tympani	(1) <u>Mandibular n.</u> (motor) (2) <u>chorda tympani</u> (sensory): trigeminal (sensory) ph. n. (preganglionic)
<b>2<sup>nd</sup> arch</b> (hyoid arch)	<u>Reichert's Cartilage</u> : differentiates into the following (from dorsal to ventral): (1) <u>Stapes</u> (2) <u>styloid process</u> (3) <u>stylohyoid lig.</u> (from the pericondrial sheath) (4) <u>lesser horn</u> & upper part of body of hyoid	(A) muscles of the scalp (B) muscles of the face (c) platysma m. of the neck. (d) stylohyoid m. & post. belly of digastric (e) stapedius m. (of tympanic cavity).	(1) <u>facial n.</u> (motor) (2) <u>trigem. br. of glossopharyngeal n.</u> (preganglionic) (3) <u>glossopharyngeal n.</u> (motor)
<b>3<sup>rd</sup> arch</b>	greater horn & lower part of the body of hyoid bone.	only one muscle of pharynx stylopharyngeus	(4) <u>external laryngeal n.</u>
<b>4<sup>th</sup> arch</b>	Thyroid cartilage of the larynx.	only one muscle of larynx: cricothyroid	
<b>5<sup>th</sup> arch</b>	<b>Degenerates</b>		
<b>6<sup>th</sup> arch</b>	all cartilages of the larynx (except the thyroid cartilage).	(1) all laryngeal muscles (except cricothyroid) (2) Constrictor muscles of pharynx. (3) muscles of palate (except tensor palati).	recurrent laryngeal nerve

## (I) Muscles of the tongue:

- derived from 3 occipital myotomes which migrate into the tongue dragging with them their nerve supply (hypoglossal n.).

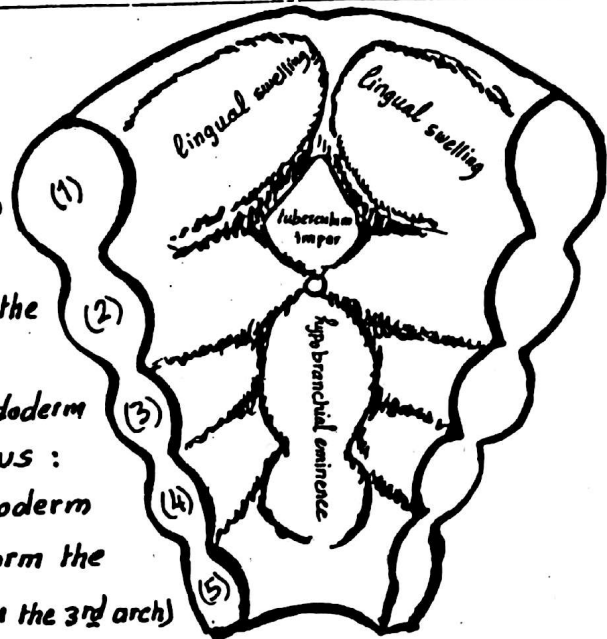
- The Course of the hypoglossal n. indicates the pathway of migration



## (II) - the mucous membrane:

(A) Ant. 2/3: arise from 3 swellings derived from the 1st pharyngeal arch:

- (1) tuberculum impar: small median elevation between the ventral ends of the 1st pharyngeal arch.
- (2) 2 lingual swellings: on either side of the tuberculum impar.



(B) Post. 1/3 of tongue: arises from the endoderm of the 3rd pharyngeal arch as follows:

- \* behind the tuberculum impar, the endoderm of the 2nd, 3rd & 4th arches fuse to form the hypobranchial eminence (mainly from the 3rd arch)

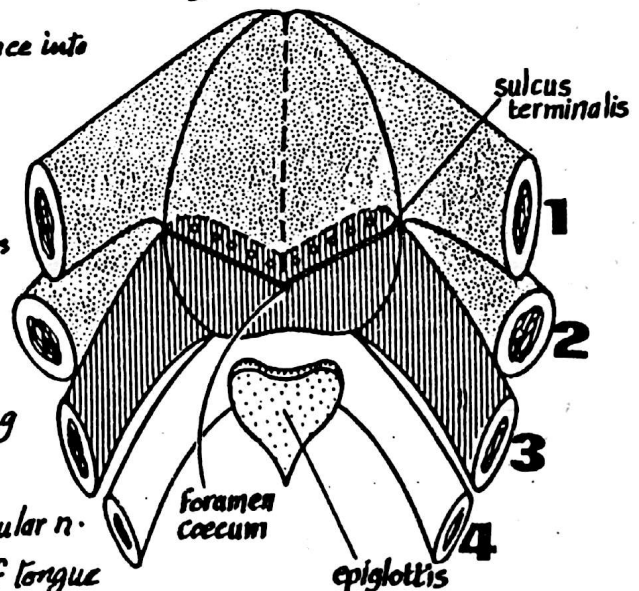
\* a groove divides the hypobranchial eminence into upper & lower parts:

- the lower part (mainly from 4th arch) forms the epiglottis.
- the upper part (mainly from 3rd arch) grows in a V-shaped manner & forms the post. 1/3 of the tongue.

\* the post. 1/3 fuses with the ant. 2/3 along the V-shaped sulcus terminalis

N.B: the nerve of the 1st arch i.e. mandibular n. supplies the ant. 2/3 of m. memb. of tongue

while the n. of the 3rd arch (glossopharyngeal n.) supplies the post. 1/3 of the muc. membrane.



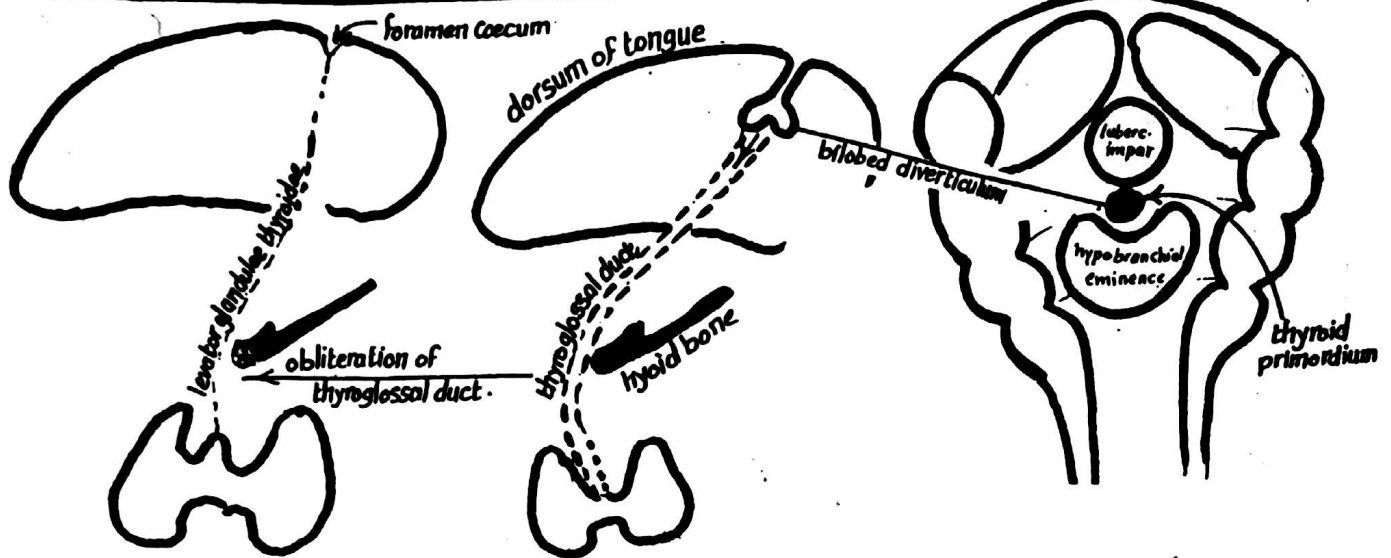
\* Congenital anomalies: (1) aglossia: complete or partial absence of tongue.

(2) macroglossia: abnormally large tongue due to hypertrophy of its muscles.

(3) bifid tongue: a rare anomaly due to failure of fusion of the 2 lingual swellings.

(4) tongue tie: the frenulum extends to the tip preventing protrusion of the tongue.


# DEVELOPMENT OF THYROID GLAND 36



- (1) Thyroid primordium appears at the 4th week as median endodermal proliferation in the floor of pharynx between the tuberculum impar & the hypobranchial eminence (at the site indicated by the f. caecum in the adult tongue).
- (2) This thickening is evaginated to form a bilobed diverticulum which descends in front of hyoid bone & laryngeal cartilages & remains connected to the dorsum of tongue by the thyroglossal duct.
- (3) The thyroid gland finally reaches its position in front of thyroid cartilage & upper part of trachea.
- (4) the thyroglossal duct becomes obliterated & disappears (or fibrosed to form the levator glandulae thyroidae).

## \* Congenital anomalies of the thyroid:

- (1) Thyroid agenesis : congenital absence of thyroid gland leading to cretinism.
- (2) Lingual thyroid : the thyroid fails to descend & lies in the substance of the tongue.
- (3) Thyroglossal cyst : due to persistence of part of the thyroglossal duct unobliterated (anywhere along the line of descent of the thyroid gland).
- (4) Thyroglossal fistula :
- (5) Aberrant thyroid : the thyroid may descend more to reach thorax (retrosternal thyroid).



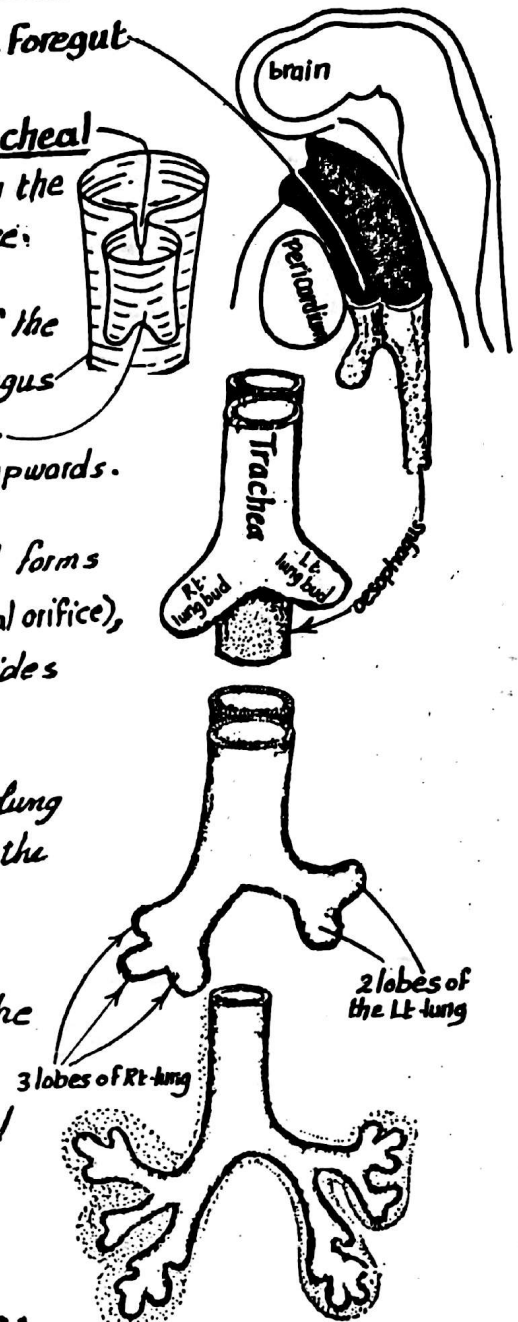
## Development of parathyroid glands:

see derivatives of the pharyngeal pouches : page 33.



**I- the Epithelium:** develops from the endoderm of the Foregut as follows:

- (1) In the 3<sup>rd</sup> week, a diverticulum called the laryngo-tracheal groove (the primordium of the respiratory system) appears in the endodermal floor of pharynx behind the hypobranchial eminence.
- (2) The edges of the groove unite, dividing the upper part of the foregut into 2 parts : the dorsal part forms the oesophagus and the ventral part forms the laryngo-tracheal tube. The union of the edges of the groove begins from below upwards.
- (3) The laryngo tracheal tube grows Caudally ; its upper end forms the larynx (which remains connected to foregut by the laryngeal orifice), the next part forms the trachea while its lower part divides into 2 lat-outpocketing called lung buds.
- (4) The Rt. lung bud divides into 3 branches while the left lung bud divides into 2 branches . Each branch is called the main bronchus .
- (5) Each bronchus branches repeatedly untill about 17 generations of subdivisions are produced forming the bronchial tree of one lobe of the lung .
- (6) the terminal branches (called respiratory bronchioles) end in the alveoli which expand only after birth with the onset of respiration.



**II- the Cartilages, muscles & connective tissue:**  
develop from the splanchnic mesoderm

## DEVELOPMENT OF THE OESOPHAGUS

- \* develops from the part of the foregut extending from the respiratory diverticulum to the fusiform swelling of the stomach .
- \* At first it is a short tube but later on it elongates rapidly with the descent of the heart & lungs .
- \* the surrounding mesenchyme differentiates to form the musculature of the oesophagus .

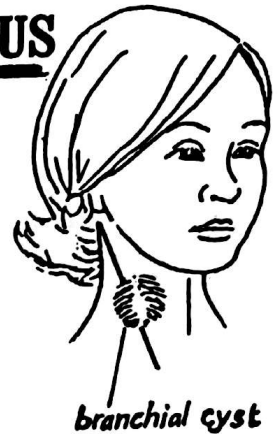## ANOMALIES OF THE PHARYNGEAL PART OF FOREGUT

### (A) ANOMALIES OF THE BRANCHIAL APPARATUS

(1) Branchial cyst: is a cystic swelling lying anywhere along the ant. border of sternomastoid m. It results from failure of obliteration of the cervical sinus (the 2nd, 3rd & 4th ectodermal clefts).

(2) Branchial sinus: the branchial cyst may open into the skin by a narrow canal forming a sinus.

(3) Branchial fistula: the branchial cyst opens into the lumen of the pharynx.



### (B) ANOMALIES OF THE TRACHEA & OESOPHAGUS:

(1) tracheo-oesophageal fistula: an abnormal opening between trachea & oesoph. due to incomplete fusion of the edges of the laryngo-tracheal groove.

(2) Oesophageal atresia: due to displacement of the septum between trachea & oesophagus posteriorly leading to narrowing of the oesophagus.

(3) oesophageal atresia with tracheo-oesophageal fistula.



### (C) Congenital anomalies of the lungs:

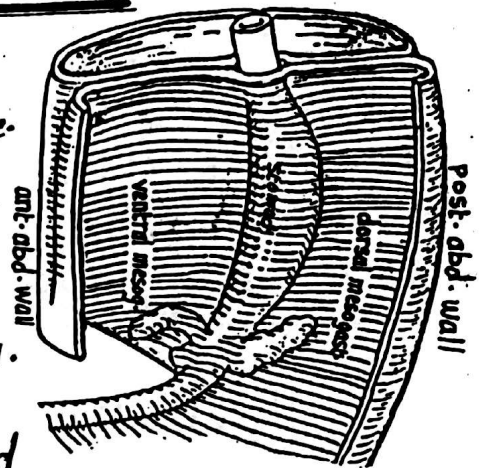
(1) agenesis of one or both lungs: an extremely rare condition resulting from failure of development of lung buds at the caudal end of the laryngo-tracheal tube.

(2) accessory lung lobes: due to additional branching of the stem of the lung bud.

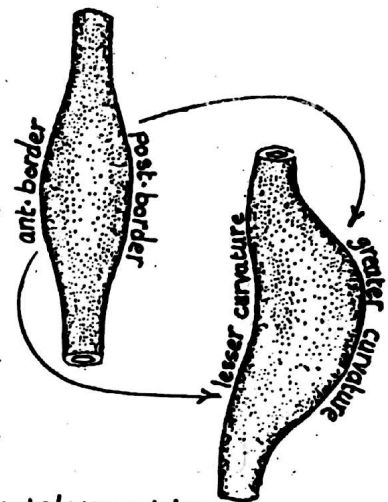
(3) Respiratory distress syndrome (Hyaline membrane disease):

failure of the alveoli to ventilate adequately due to absence of a substance called **surfactant** (necessary to overcome the surface tension forces in the alveoli when the lungs are inflated).

- (1) The stomach appears early in the 5th week as a fusiform swelling in the lower end of the foregut in the middle line. It has 2 borders : ant. & post. and 2 surfaces : Rt. & Lt. - the ant. border is connected to the ant. abd. wall by ventral mesogastrium while the post. border is connected to the post. abd. wall by dorsal mesogastrium.

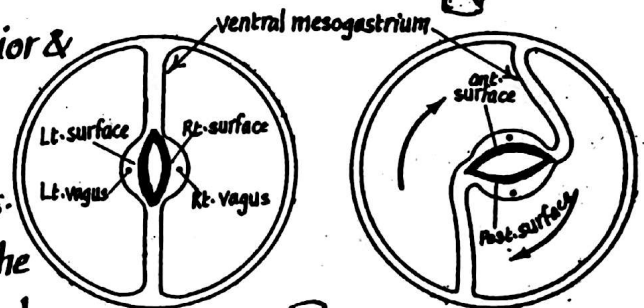


- (2) as development proceeds, both the appearance and position of the stomach changes due to variations of the positions of surrounding organs & the different rates of growth of the different parts of the stomach as follows:
- (a) the post. border grows much & forms the greater curvature.
  - (b) the ant. border grows less than the post. & forms the lesser curvature.



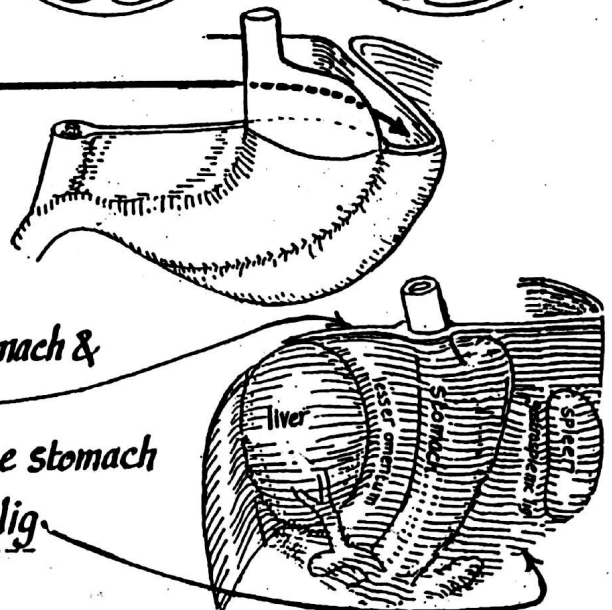
- (3) the stomach rotates 90° clockwise around its longitudinal axis & as a result :

- (a) the original Lt. surface becomes anterior & Lt. vagus becomes the ant. gastric n.
- (b) the original Rt. surface becomes post. & the Rt. vagus becomes the post. gastric n.
- (c) the dorsal mesogastrium is pulled to the left forming a pouch behind the stomach called the lesser sac of peritoneum.



- (4) As a result of development of the liver in the ventral mesogastrium & development of the spleen in the dorsal mesogastrium :

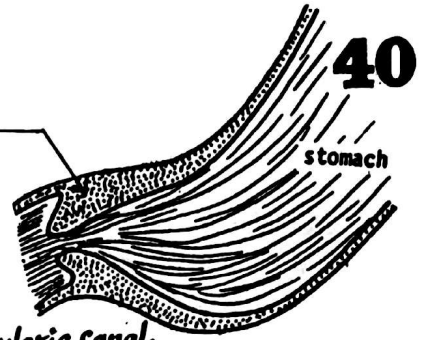
- (a) the part of mesogastrium between the stomach & liver forms the lesser omentum
- (b) the part of mesogastrium between the stomach & the spleen forms the gastro-splenic lig.



## Congenital anomalies of the Stomach:

### - Congenital hypertrophic pyloric stenosis

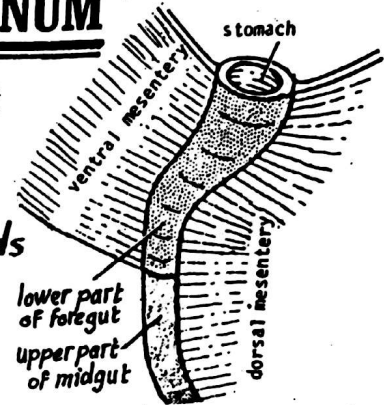
it is a relatively common anomaly characterized by marked hypertrophy & hyperplasia of the circular muscle of the pyloric sphincter resulting in narrowing of pyloric canal.



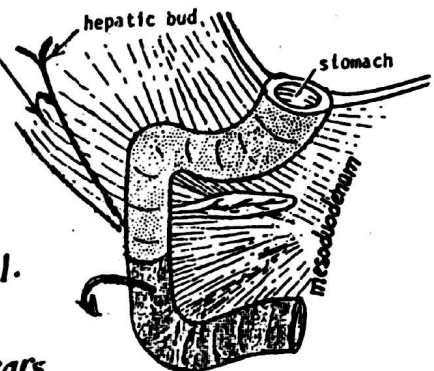
## DEVELOPMENT OF THE DUODENUM

The duodenum develops from the distal part of foregut & the proximal part of midgut as follows:

(1) the duodenum forms a U-shaped loop convex forwards in the middle line connected to the post-abd. wall by dorsal mesentery (mesoduodenum). The upper part of the duodenal loop has also a ventral mesentery



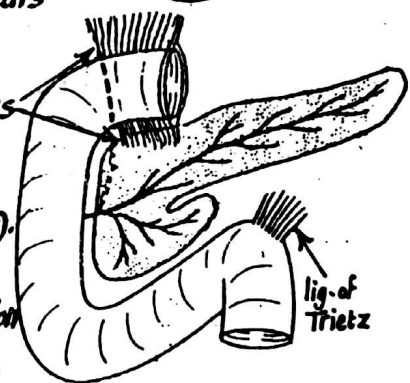
(2) As a result of rotation of the stomach 90° in clockwise direction, the duodenal loop is carried dorsally & to the right against the post-abdominal wall & the peritoneum on the post-surface of duodenum disappears & the duodenum becomes adherent to the post-abd. wall.



(3) The mesentery of the duodenum degenerates & disappears except:

- (a) the 1<sup>st</sup> inch of the 1<sup>st</sup> part which retains its mesenteries
- (b) the 4<sup>th</sup> part whose dorsal mesentery remains as the suspensory lig. of the duodenum (Ligament of Trietz).

(4) the lumen of the duodenum shows temporary obstruction by proliferation of the lining epithelium but it rapidly becomes canalized again.



### \* Congenital anomalies:

- (1) incomplete canalization leading to stenosis of the duodenum.
- (2) incomplete fixation of duodenum to the post-abd. wall leading to extensive paraduodenal recesses which may be sites of internal hernia.



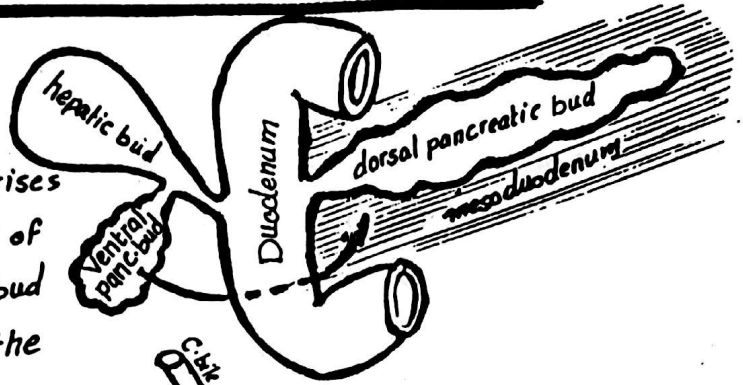
# DEVELOPMENT OF PANCREAS

41

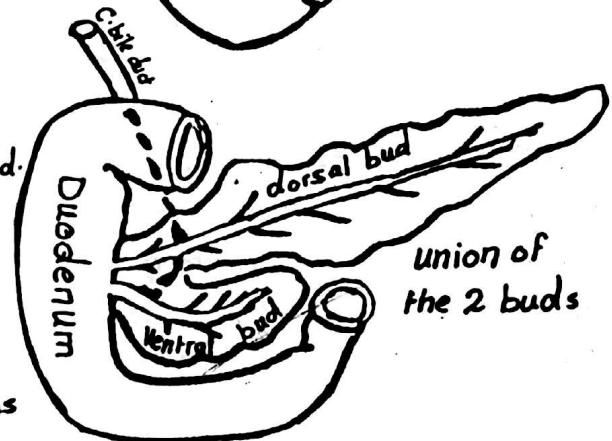
(1) The pancreas develops in the 4<sup>th</sup> week from 2 endodermal buds:

(a) **Dorsal Pancreatic bud** which arises from the endoderm of the dorsal wall of the duodenum slightly above the liver bud and extends dorsally & upwards into the mesoduodenum.

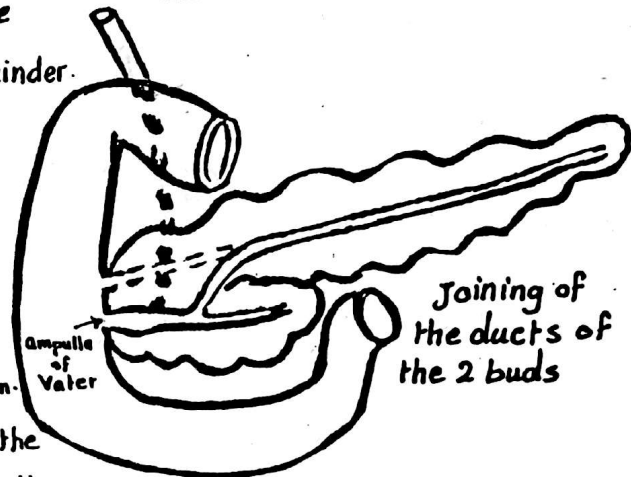
(b) **Ventral pancreatic bud** which arises from the ant. wall of the stem of the hepatic bud.



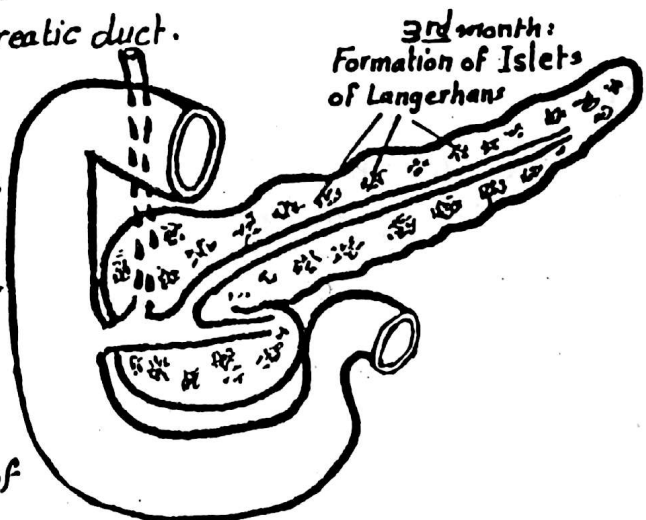
(2) In the 7<sup>th</sup> week, the ventral bud migrates dorsally to lie just below & behind the dorsal bud. The 2 buds fuse together to form the pancreas. The ventral bud forms the greater part of the head & the uncinate process while the dorsal bud forms the remainder of the pancreas.



(3) Later on, the ducts of the dorsal & ventral pancreatic buds join each other to form the main pancreatic duct which is joined by the common bile duct to form the ampulla of Vater opening into the duodenum. The part of the dorsal pancreatic passing to the duodenum is obliterated but occasionally it remains patent forming the accessory pancreatic duct.



(4) the Islets of Langerhans appear in the 3<sup>rd</sup> month but insulin secretion begins about the 5<sup>th</sup> month.



## \*Congenital anomalies:

(1) annular pancreas: the pancreas may form a ring encircling the 2<sup>nd</sup> part of duodenum completely.

(2) Ectopic pancreatic tissue: e.g. in the wall of the duodenum.

# DEVELOPMENT OF LIVER AND GALL BLADDER<sup>42</sup>

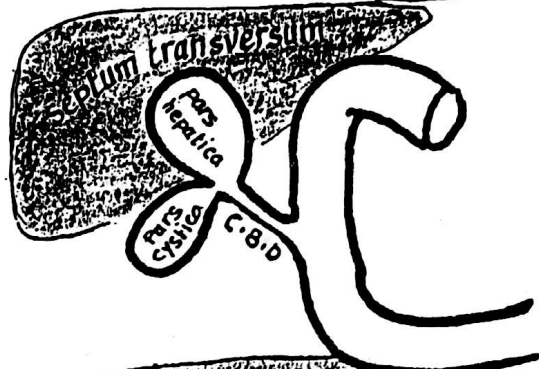
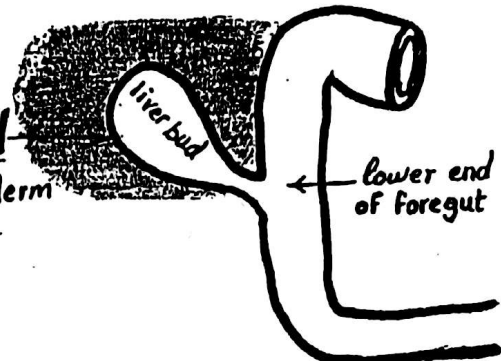
\* The liver & gall bladder arise from the endoderm of the foregut as follows:

(1) In the middle of the 3<sup>rd</sup> week, a liver bud (hepatic diverticulum) develops from the endoderm of the lower end of foregut.

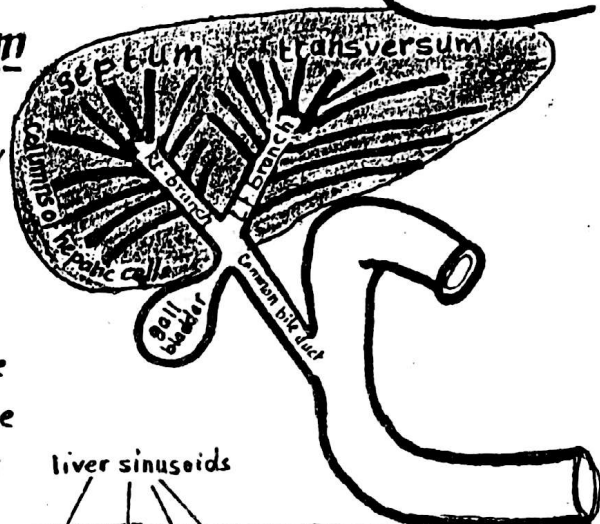
(2) the liver bud divides into 2 parts:

(a) pars hepatica : is the large cranial part which will give the future liver

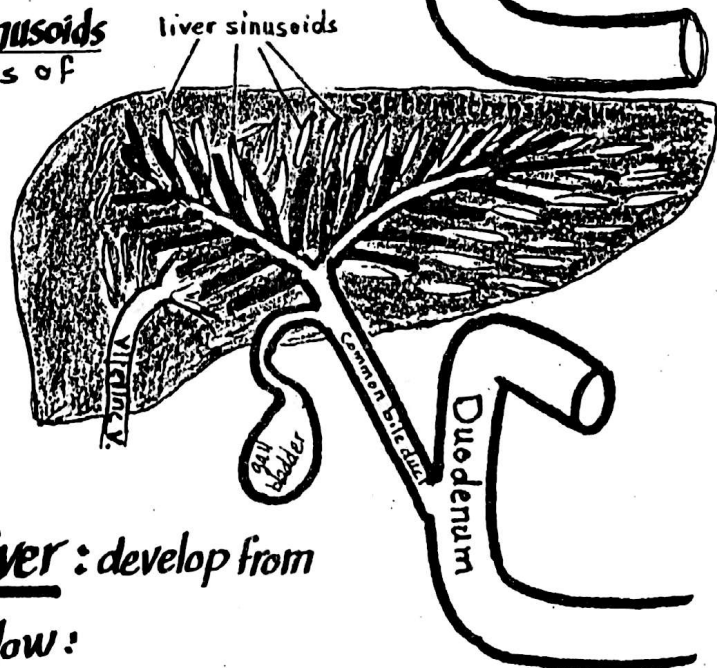
(b) pars cystica : is the small caudal part which will give the future gall bladder - the original stalk of the liver bud will form the Common bile duct.



(3) The pars hepatica invades the septum transversum & divides into Rt. & Lt. branches. Each branch divides repeatedly to form the columns of hepatic cells of one lobe of the liver.

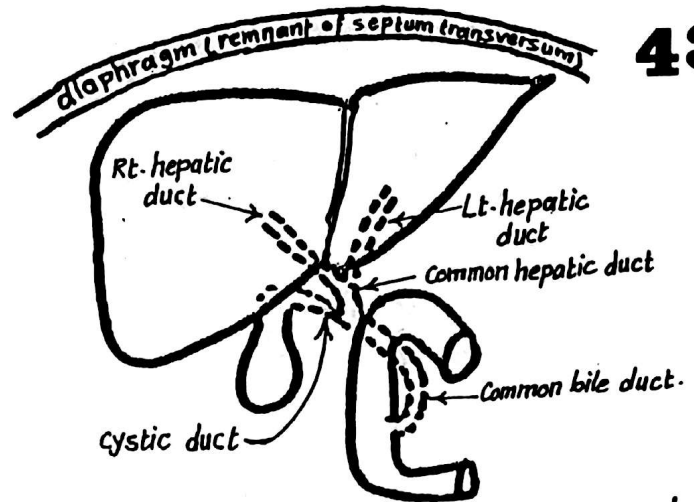
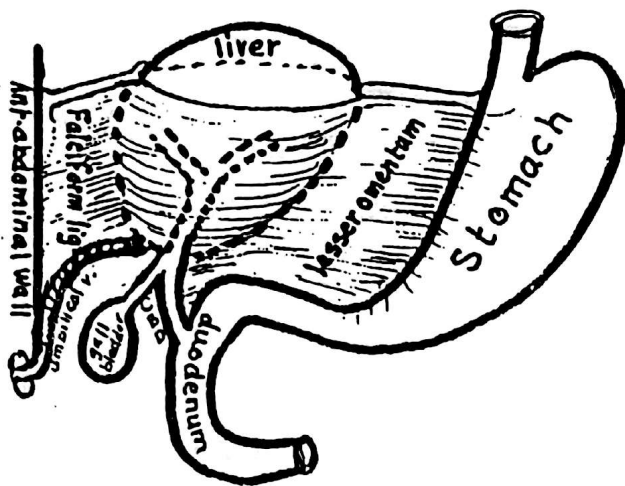


(4) The columns of the hepatic cells inside the septum transversum meet the vitelline veins breaking them into liver sinusoids which intervene between the cords of the liver cells.



(5) the mesoderm of the septum transversum gives rise to the fibrous tissue stroma and the capsule of the liver.

(6) The Ligaments of the liver : develop from the septum transversum as follow :



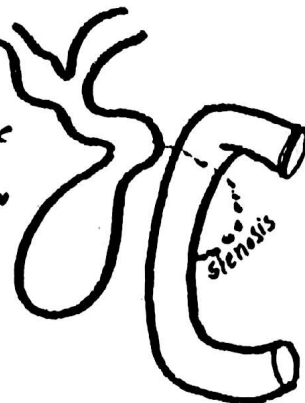
- (a) The mesoderm of septum transversum between the liver & the ant.-abdominal wall becomes stretched & forms the Falciform ligament & the umbilical V. originally traversing the septum lies in the free margin of the falciform lig.
- (b) The mesoderm of the septum transversum lying between the liver & the stomach becomes stretched to form the lesser omentum.
- (c) The liver separates from the septum transversum (the remnant of which will form part of the diaphragm). Only a small area (the bare area of liver) remains in contact with the septum transversum.

### (7) The Ducts of the liver develop as follows :

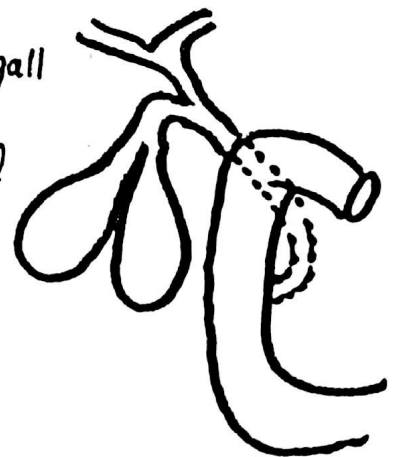
- (a) the Rt. & Lt. hepatic ducts develop from the stems of the Rt. & Lt. branches of the pars hepatica.
- (b) the original stalk of the liver bud elongates to form the Common bile duct which opens at first into the ant.-wall of the duodenum.
- (c) Later, as a result of rotation of the stomach the opening of the C.B.D migrates to the posteromedial aspect of the 2<sup>nd</sup> part of duodenum.

### \* Congenital anomalies:

- (1) Congenital atresia of the Common bile duct with distension of gall bladder & biliary passages.



- (2) Duplication of gall bladder which may be partial or complete.



# DEVELOPMENT OF THE MIDGUT

44

\* the midgut is the part of the gut which extends from the ant. intestinal portal to the post. intestinal portal.

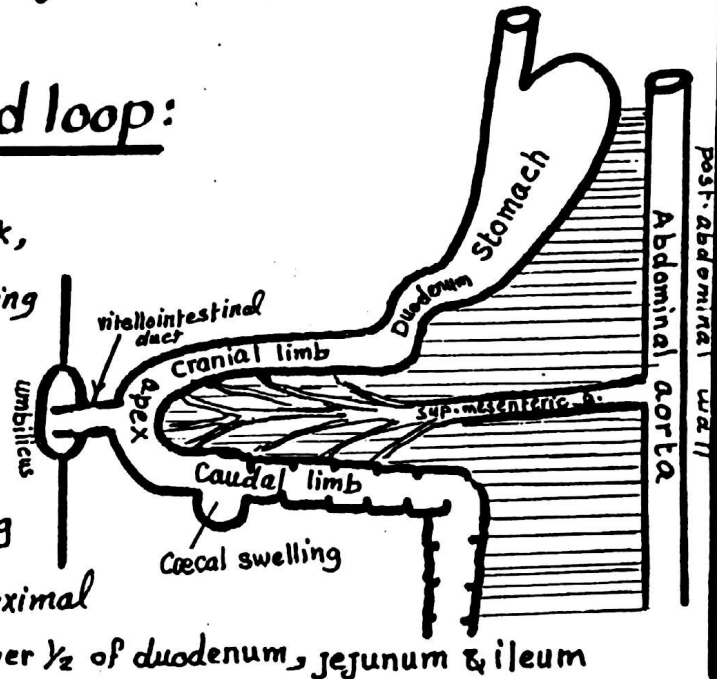
## \* Derivatives:

- the lower  $\frac{1}{2}$  of duodenum, the jejunum & ileum.
- the Caecum, appendix, ascending Colon & Rt. 2/3 of transverse Colon.

## \* Development:

### I- Formation of U-shaped loop:

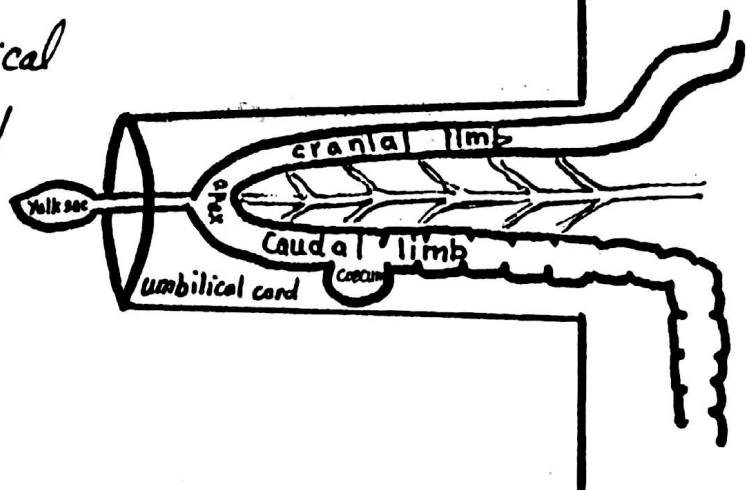
- (1) At the beginning of the 5<sup>th</sup> week, the part of the primitive gut extending between the ant. & post. Intestinal portals forms a U-shaped loop which has cranial limb, apex & Caudal limb showing a Caecal swelling
- (2) The Part of the U-shaped loop proximal to the Caecal swelling will form the lower  $\frac{1}{2}$  of duodenum, jejunum & ileum
- (3) the apex of the loop is connected to the yolk sac via the vitello intestinal duct
- (4) the part forming the Caecal swelling will develop into caecum & appendix.
- (5) the part distal to the " " will develop into ascending colon & Rt. 2/3 of the transverse colon.



### II- Herniation of the intestinal loop into the umbilical Cord:

At the 6<sup>th</sup> week, the intestinal loop elongates rapidly forming many loops which leave the abdominal cavity (which is, at that time, very small) and enter the umbilical cord.

This is called physiological umbilical hernia which remains till the end of the 10<sup>th</sup> week.



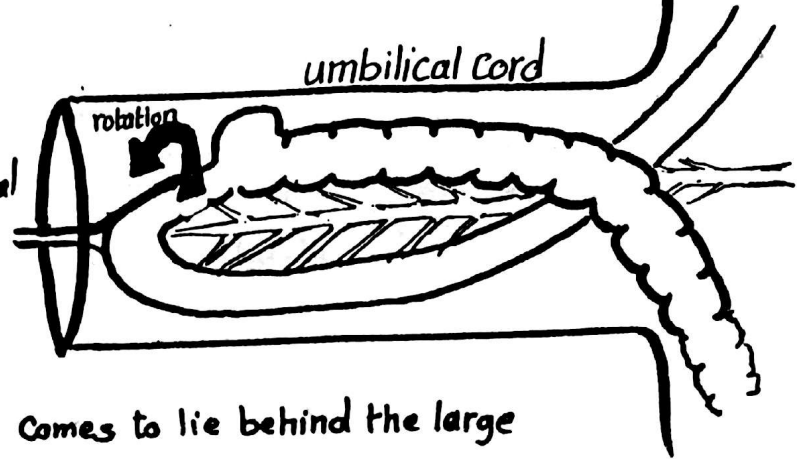


### III- Rotation of the intestinal loop 270° anticlockwise:

45

in the same time in which the intestinal loop is elongating, it rotates 270° in an anticlockwise direction around a longitudinal axis formed by the sup. mesenteric artery.

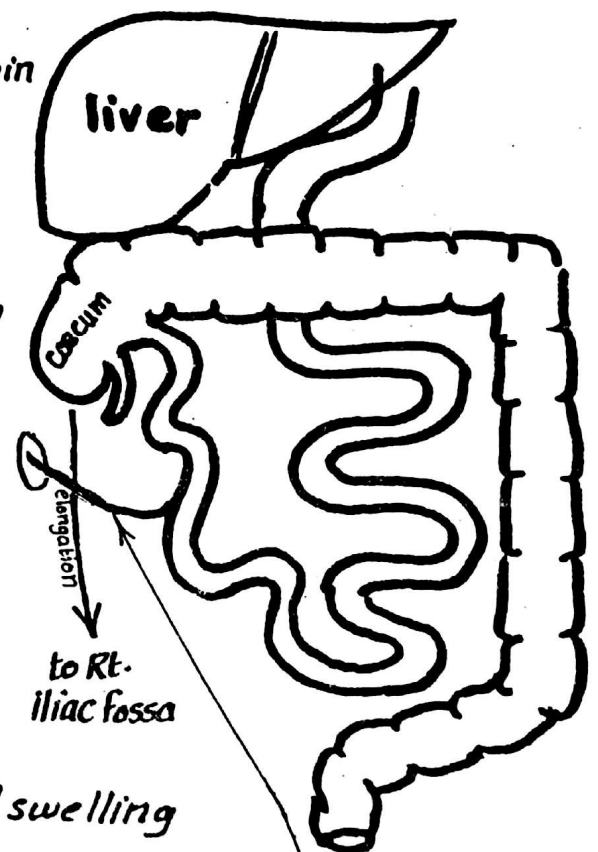
As a result of this rotation, the upper part of the small intestine comes to lie behind the large intestine.



### IV Reduction (return) of the intestinal loops into the abdomen:

At the 10<sup>th</sup> week, the abdominal cavity enlarges and the herniated loops begin to return to the abdominal cavity in a special order.

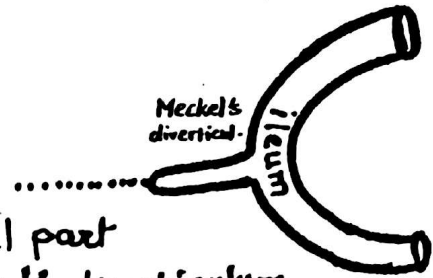
- the upper part of the jejunum is the 1<sup>st</sup> part to re-enter the abdomen and lies on the left side.
- the next returning loops gradually lie more & more to the Rt. side.
- the Coecal swelling is the last part to return to the abdominal cavity and lies below the liver.
- As development proceeds the Coecal swelling elongates downwards to reach the Rt. iliac Fossa thus forming the Rt. Colic Flexure & ascending colon.
- The Vitello-intestinal duct finally becomes obliterated.



## I-- REMNANTS OF VITELLINE DUCT

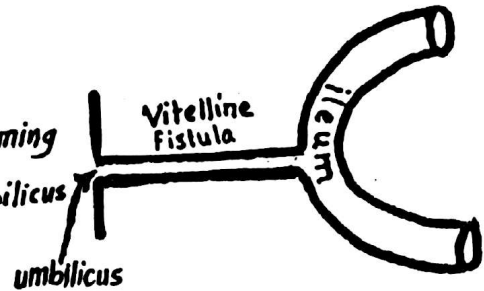
### (1) Meckel's diverticulum:

The Vitelline duct normally becomes obliterated & disappears completely. Sometimes its proximal part near the ileum remains patent forming the Meckel's diverticulum. Meckel's diverticulum is 2" long, present in 2% of people, attached to the ileum 2 feet from the ileocaecal valve.



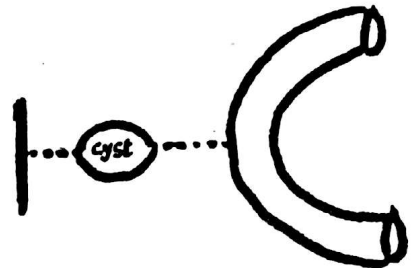
### (2) Vitelline Fistula:

The whole vitelline duct remains open forming a direct connection between the intestine & umbilicus (foecal Fistula).



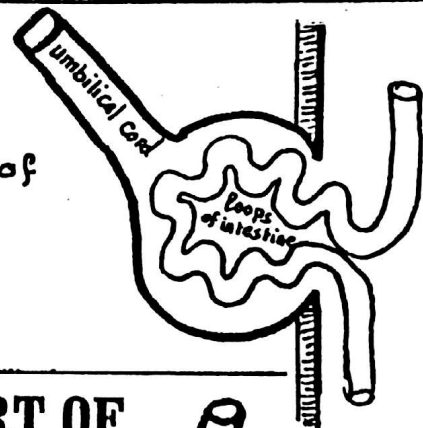
### (3) Vitelline cyst:

Both ends of the vitelline duct change into fibrous cords while its middle part remains patent forming an intra-abdominal cyst.



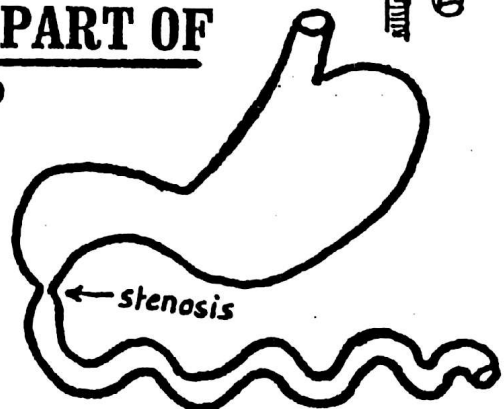
## II--OMPHALOCELE

loops of small intestine may remain inside the umbilical cord at birth due to failure of reduction of the physiological hernia.



## III-- ATRESIA & STENOSIS OF ANY PART OF THE PRIMITIVE INTESTINAL LOOP

stenosis may affect any part of the primitive loop, most commonly the duodenum.

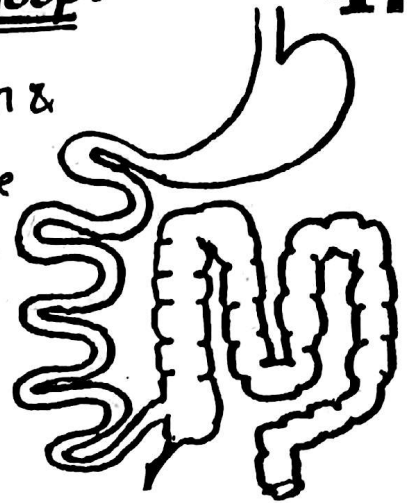


#### IV- Abnormal rotation of the intestinal loop:

47

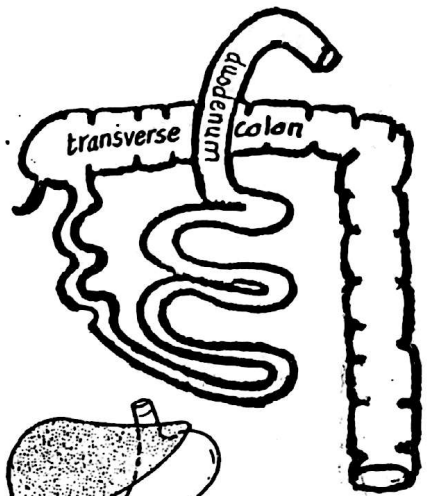
(a) if rotation occurs for 90 degrees only, the colon &

Caecum will be the 1<sup>st</sup> parts to re-enter the abdomen (from the umbilical cord) & will be on the left side of the abdominal cavity while the small intestine will lie to the Rt. side.

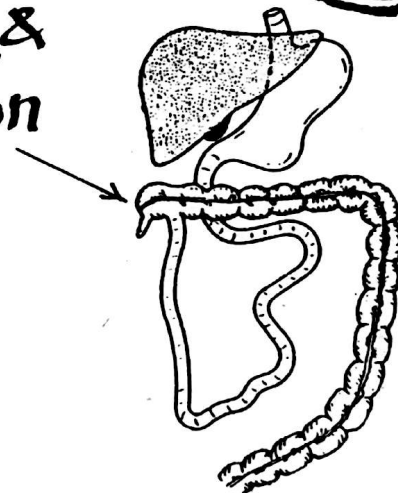


(b) reversed rotation of the intestinal loop:

reversed rotation i.e in a clockwise direction will bring the transverse colon to lie behind the duodenum.



#### V- Abnormal site of the Caecum & appendix e.g subhepatic position



#### VI- Lt. sided Caecum & appendix:

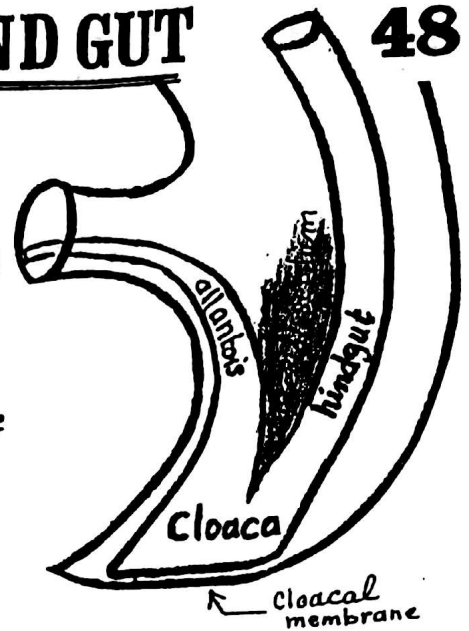
may be due to arrested rotation of the midgut or a part of situs inversus (transposition of thoracic & abdominal viscera).

# DEVELOPMENT OF HIND GUT

48

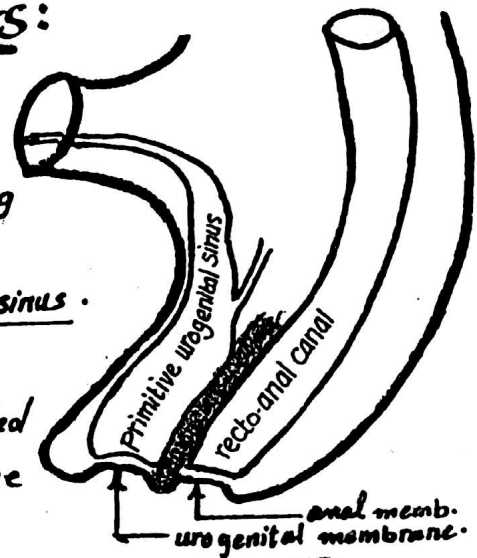
## I- Formation of the Cloaca:

- \* the lower end of the hindgut dilates to form an expanded part called the cloaca (endodermal)
- \* the Cloaca is Connected to the umbilicus by the allantois & Closed below by the cloacal membrane which is bilaminar i.e formed of 2 layers :
- (a) outer ectodermal layer &
- (b) inner endodermal layer.



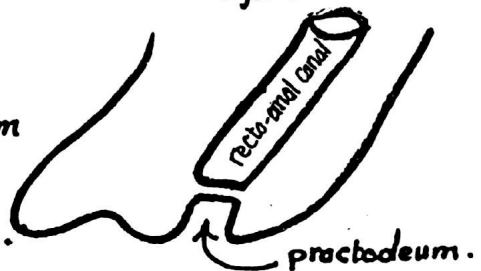
## II- Division of the Cloaca into 2 parts:

- \* The tissue between the hindgut & allantois forms the uro-rectal septum which grows caudally towards the cloacal membrane dividing the cloaca into :
- (a) an anterior part called the primitive uro-genital sinus.
- (b) a posterior " " " ano-rectal canal.
- \* At the same time the cloacal membrane is divided into urogenital membrane anteriorly & anal membrane posteriorly.



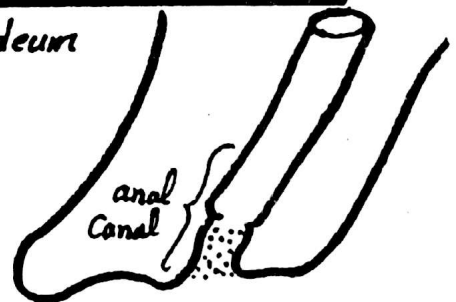
## III- Formation of the proctodeum:

an ectodermal depression called the proctodeum is formed opposite the lower end of the recto-anal canal & is separated from it by the anal membrane.



## IV- Rupture of the anal membrane & formation of anal canal:

- \* the anal membrane finally ruptures & the proctodeum becomes continuous with the recto anal canal.
- \* the recto anal canal will form the rectum + the upper  $\frac{1}{2}$  of the anal canal.
- \* the proctodeum will form the lower  $\frac{1}{2}$  of the anal canal.



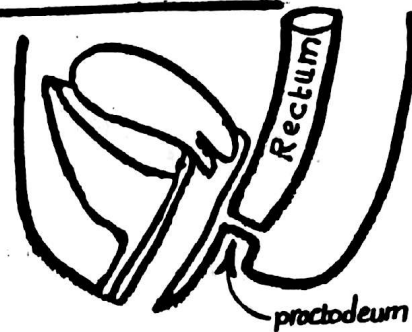


## \* Derivatives of the hind gut:

- (1) Lt.  $\frac{1}{3}$  of transverse colon (2) descending colon (3) sigmoid colon  
(4) rectum (5) upper  $\frac{1}{2}$  of the anal canal

## CONGENITAL ANOMALIES OF THE HIND GUT

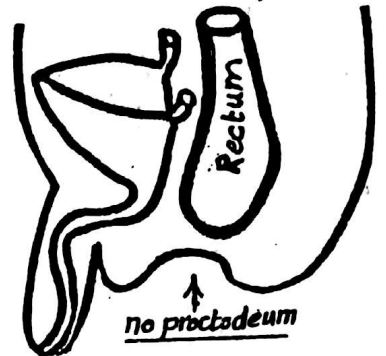
- (1) Imperforate anus: due to failure of rupture of the anal membrane (between the endodermal and ectodermal parts of the anal canal)



Imperforate anus

- (2) Atresia of rectum:

due to failure of development of the proctodeum, the rectum ends blindly & is separated from the surface by a mass of connective tissue.

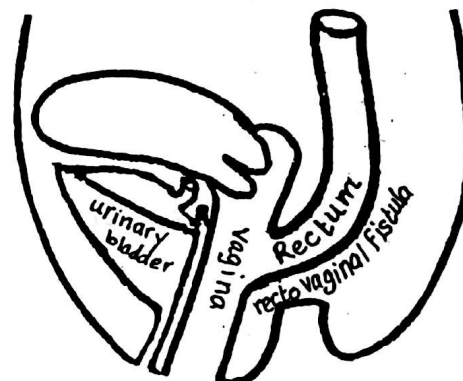


atresia of rectum

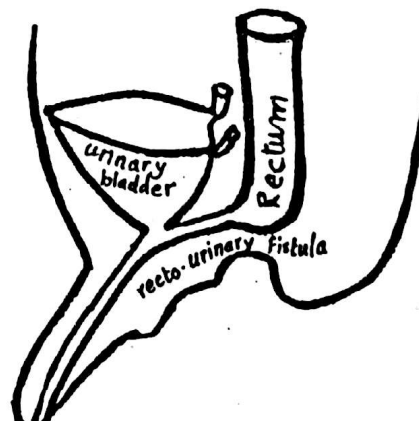
- (3) Recto-Vaginal Fistula &

- (4) Recto-urinary fistula:

these are seen frequently with imperforate anus & caused by incomplete division of the cloaca into 2 parts so, the rectum remains connected to the urinary bladder, urethra or vagina.



recto vaginal fistula



recto urinary fistula

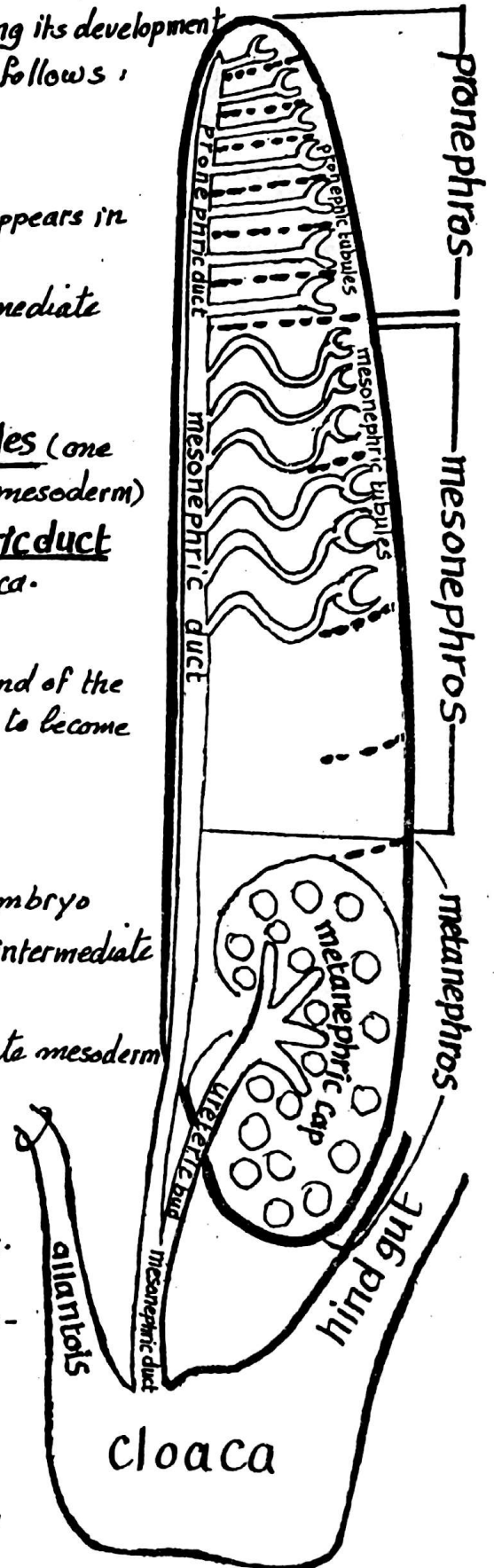
- \* The kidneys, ureters & the trigone of the urinary bladder develop from the intermediate mesoderm while the rest of " " & urethra " " endoderm
- \* The human embryo develops 3 kidneys during its development pronephros, mesonephros & metanephros as follows :

## (1) PRONEPHROS

- \* it is the 1st & simplest kidney system which appears in the human embryo.
- \* **Site:** develops in the cervical part of the intermediate mesoderm (segmented)
- \* **Structure:**
  - (a) 7-10 excretory tubules called pronephric tubules (one tubule from each segment of the intermediate mesoderm)
  - (b) a longitudinal collecting duct called Pronephric duct which extends downwards to open into the Cloaca.
- \* **Function:** no function in the human embryo.
- \* **Fate:** the tubules degenerate completely by the end of the 4th week while the pronephric duct persists to become the mesonephric duct.

## (2) MESONEPHROS

- \* It is the 2nd kidney system to appear in the embryo
- \* **Site:** thoracic & upper lumbar region of the intermediate mesoderm.
- \* **Structure:** each segment of the intermediate mesoderm develops 2-3 or more excretory tubules called mesonephric tubules. Each tubule is S-shaped & has:
  - (a) medial end invaginated by a glomerulus.
  - (b) lateral end opening into the longitudinal mesonephric duct (the pronephric duct).
- \* **Function:** no urinary function in man.
- \* **Fate:** the majority of the tubules disappear by the end of the 2nd month while few



tubules persist near the testis or the ovary. The mesonephric duct disappears in the ♀ while in the ♂ it forms the vas deferens. the important derivatives of the mesonephros are the following:

51

Part	Fate in the male embryo	Fate in the female embryo
Meso-nephric tubules	* the upper tubules degenerate * the middle & lower tubules form the efferent ductules of the testis, head of epididymis & the paradidymis	degenerate, few rudimentary tubules remain forming epioophoron } in the mesovarium paroophoron } ovary
Meso-nephric duct	forms body & tail of the epididymis, the vas deferens, the ejaculatory duct, the seminal vesicle & the ureteric bud & the trigone of the bladder	gives the ureteric bud, trigone of the bladder & a rudimentary duct called Gartner's duct.

### (3) METANEPHROS

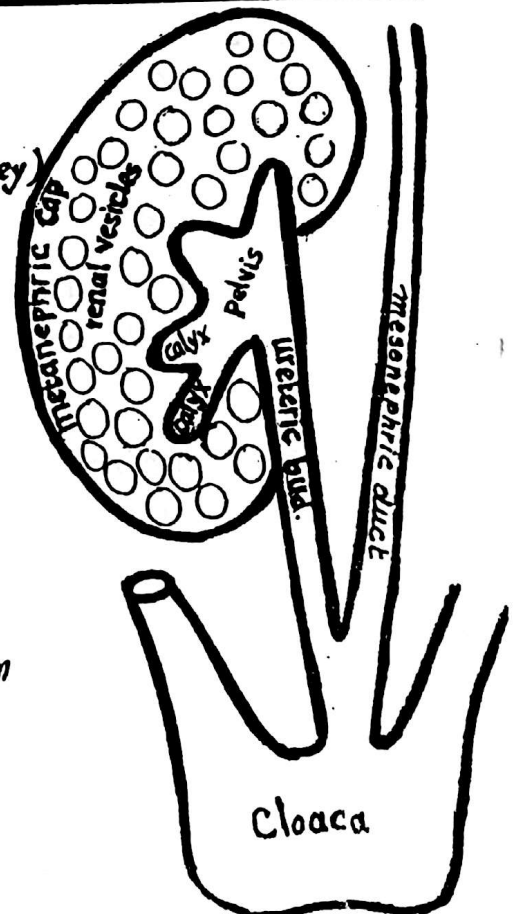
\* It is the 3rd kidney to develop (the permanent kidney)

\* Site: lumbosacral region.

\* Structure: It has a double origin:

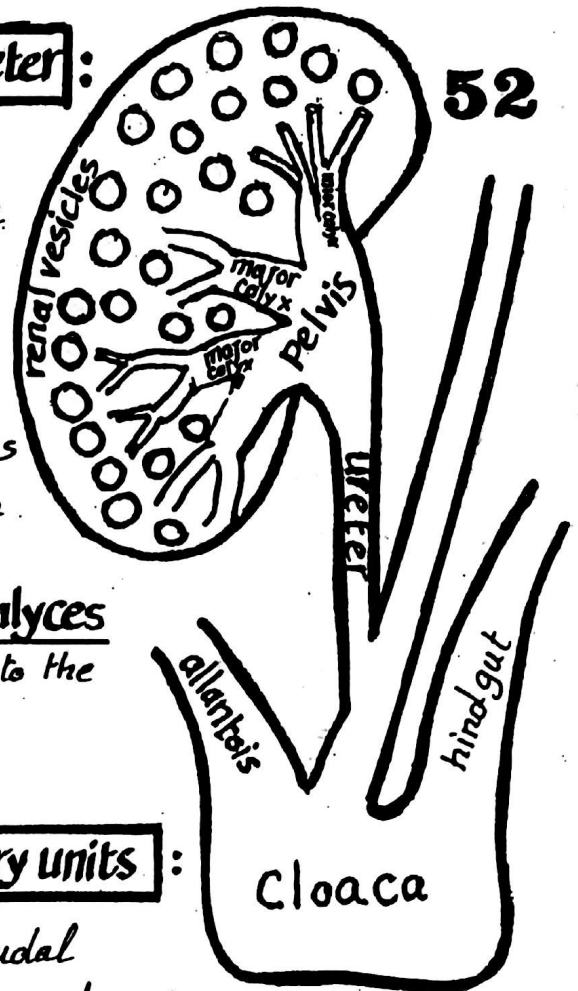
(1) nephrons: (the excretory units) develop from the metanephric cap which is the lower part of the intermediate mesoderm

(2) collecting tubules & ureter: develop from the ureteric bud which arises as a diverticulum from the mesonephric duct.



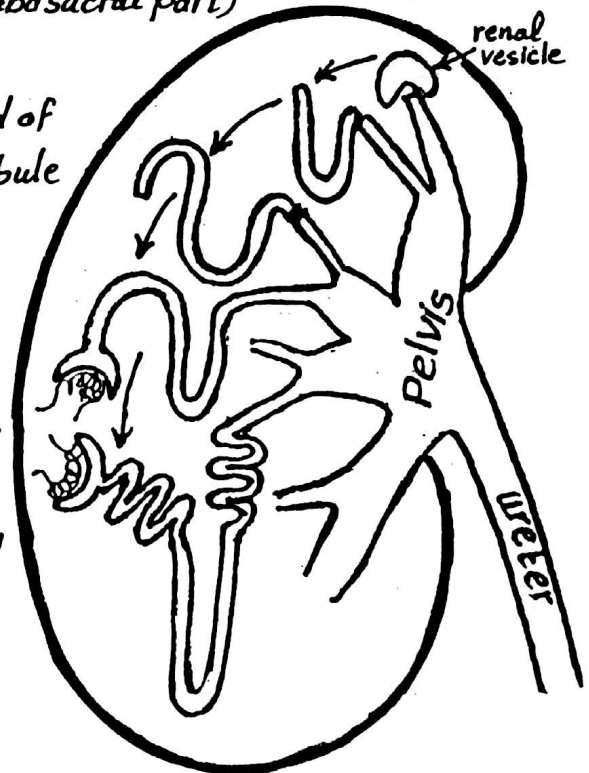
## I- Development of collecting tubules & ureter :

- \* A ureteric bud develops as a diverticulum from the dorso-medial part of the mesonephric duct close to its entrance into the Cloaca.
- \* the ureteric bud grows cranially penetrating the metanephric cap.
- \* then, the upper end of the ureteric bud enlarges to form the primitive pelvis of the ureter which divides into 2-3 major calyces
- \* each major calyx then divides into minor calyces & collecting tubules which become connected to the nephrons of the metanephric cap.



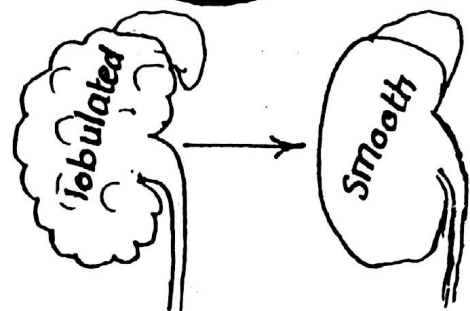
## II- Development of the nephrons (excretory units) :

- \* The metanephric cap develops from the caudal part of the intermediate mesoderm (lumbosacral part) & divides into spherical masses
- \* Each renal vesicle surrounds the free end of a collecting tubule & forms S-shaped tubule called the nephron.
- \* one end of the nephron is invaginated by a glomerulus forming Bowman's Capsule while the other end of the nephron joins the collecting tubule.
- \* each nephron elongates to form the proximal & distal convoluted tubules & the loop of Henle.



## III- Further growth of the kidney :

(1) Changes in shape : in the early stages the kidney is a lobulated organ, later the grooves disappear & its surface becomes smooth.



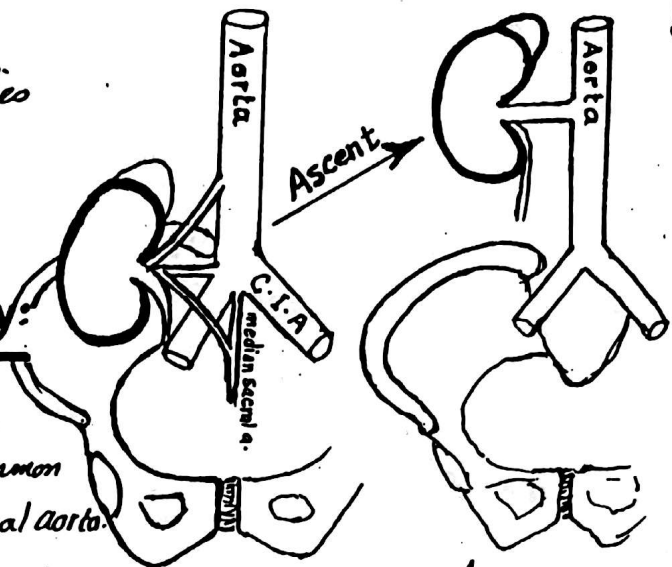


## 2- Ascent of the kidney:

- \* in the early stages, the kidney lies in the pelvic region.
- \* later it migrates upwards to the adult level.

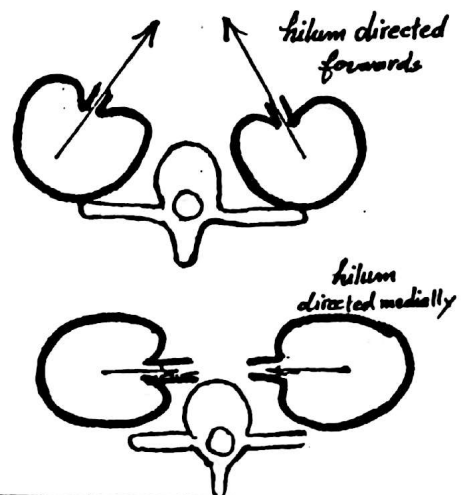
## 3- Change in the blood supply:

- \* At first the kidney receives blood supply from the median sacral, common iliac arteries & lower part of abdominal aorta.
- \* As the kidney ascends, it receives blood supply from the aorta only.



## 4- Rotation:

- \* at first the convex border of the kidney is directed backwards & the hilum is directed forwards.
- \* Later, the kidney rotates 90° so that the convex dorsal border becomes lateral & the hilum becomes medial.



# CONGENITAL ANOMALIES OF THE KIDNEY

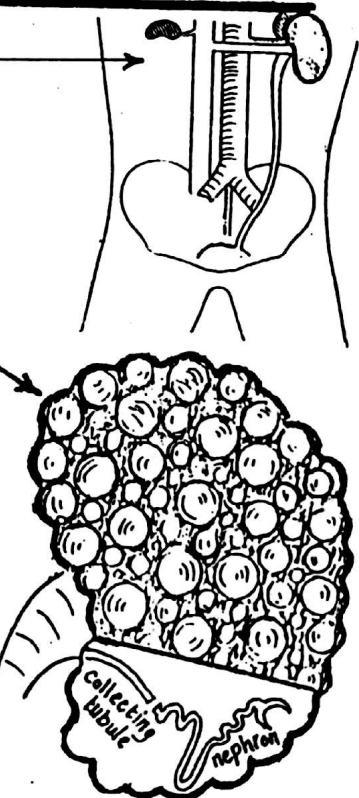
(1) Renal agenesis: failure of the development of the kidney (unilateral or bilateral).

(2) Renal hypogenesis: abnormally small-sized kidney.

(3) Congenital polycystic kidney:

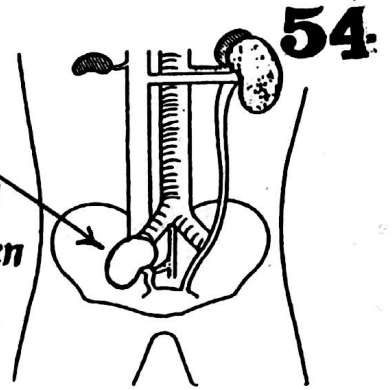
a congenital anomaly in which there is failure of fusion between the excretory units (nephrons) and the collecting tubules.

effect: urine collects in the nephrons which dilate and form cysts filled with urine. It ends in renal failure in the adult life due to destruction of the nephrons.



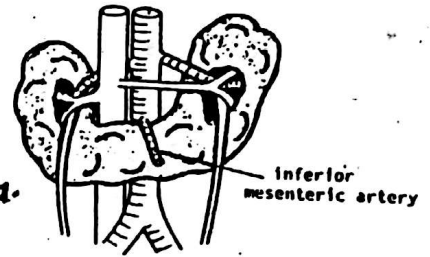
#### 4- Pelvic kidney:

the kidney retains its initial foetal position in the pelvis due to arrest of its normal ascent. It may be normal in function but if it becomes diseased later in life, the diagnosis is mistaken due to its ectopic position.



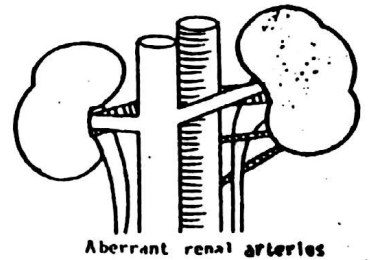
#### 5- Horse shoe-shaped kidney:

this is due to fusion of the lower poles of the 2 kidneys during their ascent from the pelvis to the abdomen where they pass through an arterial fork formed by the 2 umbilical aa. The 2 ureters are kinked as they cross over the connecting bridge of renal tissue & this produces urinary stasis with subsequent stone formation & infection.



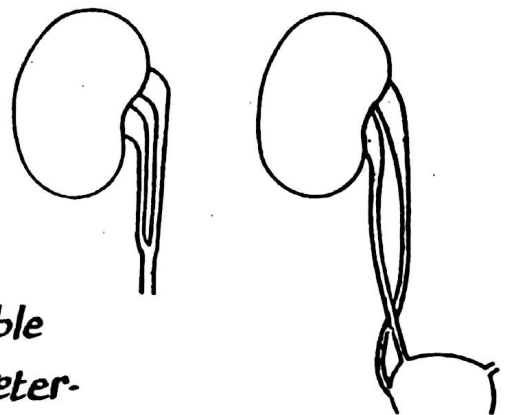
#### 6- Aberrant renal vessels:

these are additional branches of the aorta supplying the kidney (unilateral or bilateral). If they pass to the lower pole of the kidney, they often cross in front of the ureter compressing it & causing urinary stasis.



#### 7- Double ureter:

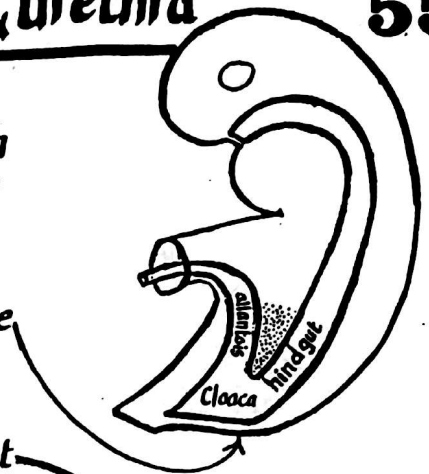
this anomaly results from either development of 2 ureteric buds on one side or due to early splitting of the ureteric bud (before reaching the metanephric cap). Double ureter is more liable to infection & stone formation than the normal ureter.



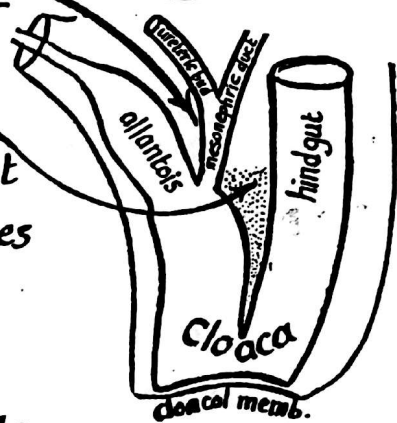
# Development of the Urinary bladder & urethra

55

- (1) The lower end of the hindgut expands to form a dilatation called the cloaca (endodermal). The cloaca is connected to the umbilicus by a duct called the allantois & is closed below by a membrane called cloacal membrane which is bilaminar (inner endoderm & outer ectoderm)

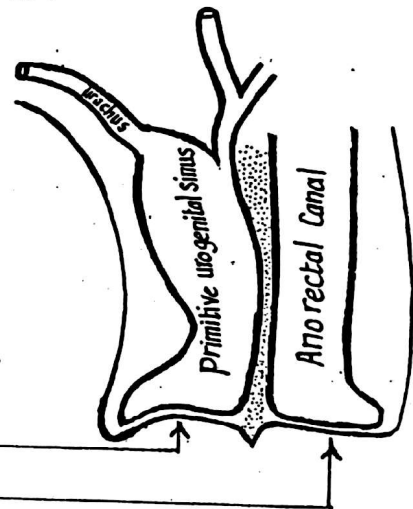


- the Cloaca is pierced on each side by the mesonephric duct
- (2) A mesodermal tissue called the uro-rectal septum develops in the angle between the allantois & the hindgut it grows caudally, cutting through the cloaca, till it fuses with the cloacal membrane.



- (3) The Cloaca becomes divided by this septum into 2 parts:

- (a) posterior part called anorectal canal which develops into the rectum & upper part of anal canal (see p. 41)
- (b) anterior part called the primitive urogenital sinus which develops into the urinary bladder & urethra.

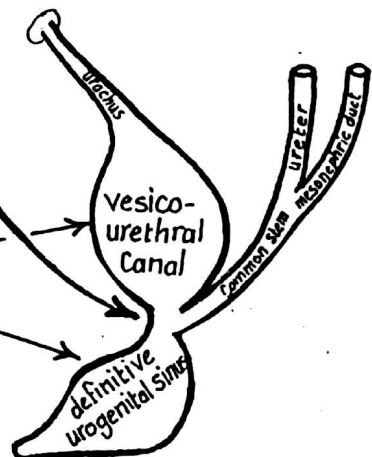


- The Cloacal membrane becomes also divided into 2 parts:

- (a) urogenital membrane anteriorly
- (b) anal membrane posteriorly

- (4) A Constriction appears in the urogenital sinus at the site of entrance of mesonephric duct dividing it into 2 parts:

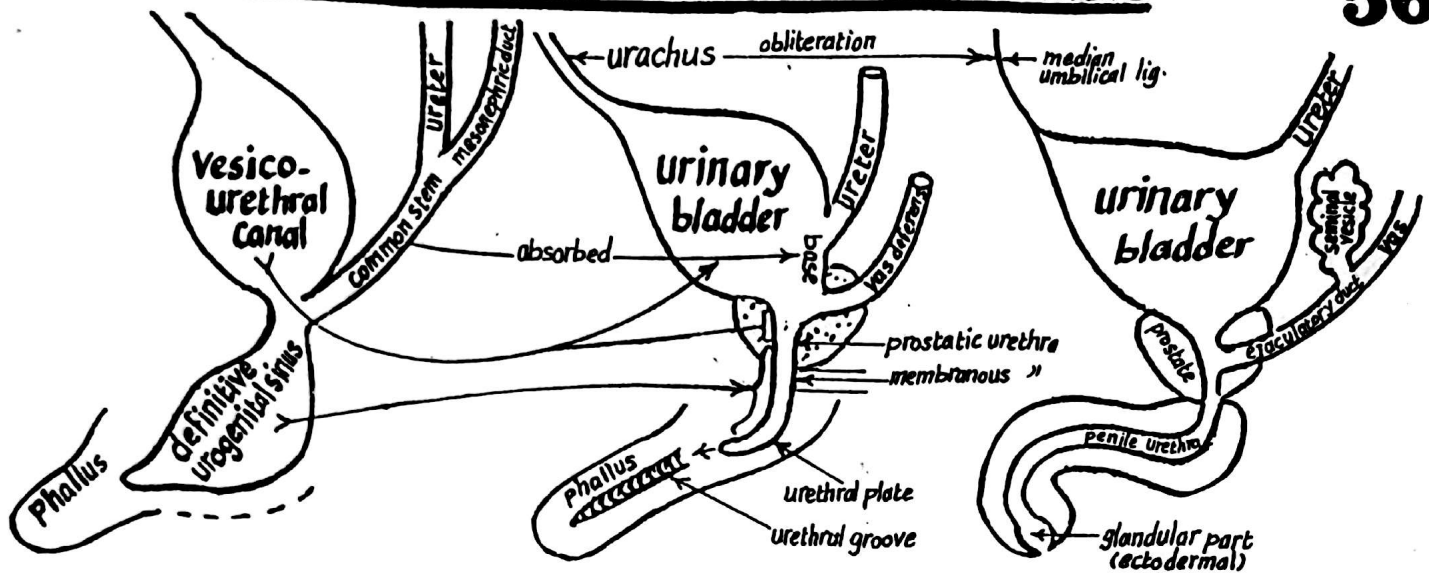
- (a) an upper part called vesico-urethral canal.
- (b) a lower part called definitive urogenital sinus.



- (5) Further development of these 2 parts differs in the male & the female embryo as follows:

## A- Development of urinary bladder in the male:

56



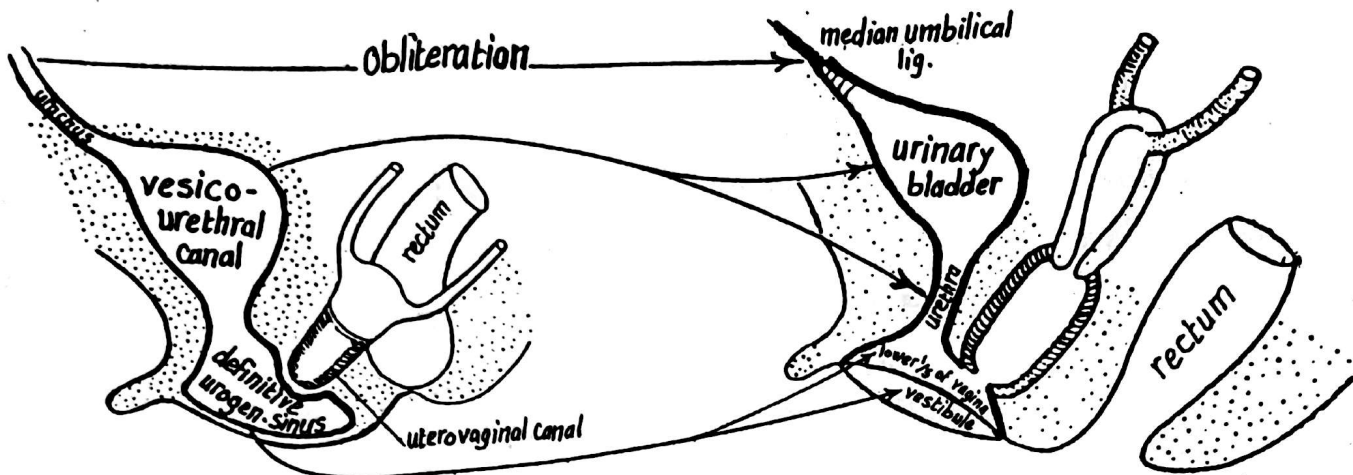
- the Vesico-urethral canal develops into the urinary bladder & the upper  $\frac{1}{2}$  of the prostatic urethra.
- the common stem of the mesonephric duct & the ureter becomes absorbed into the urinary bladder forming its trigone (mesodermal) thus the ureter & the ejaculatory duct open separately into the urinary bladder.
- With differential growth of the post-bladder wall, the opening of the ureter moves upwards to the postero superior angle of the bladder while the Vas deferens (formerly the mesonephric duct) moves downwards to the prostatic urethra limiting the part derived from the vesico urethral canal.
- the lower  $\frac{1}{2}$  of the prostatic urethra + the membranous urethra develop from the upper (pelvic) part of the definitive urogenital sinus.
- the penile urethra develops as follows:

- a urethral plate (endodermal) extends from the lower (phallic) part of the definitive urogenital sinus on the undersurface of the phallus (primitive penis) surrounded by 2 genital (urethral) folds.
- the 2 urethral folds unite from behind forwards around the urethral plate to form the penile urethra which is lined by endoderm except its terminal (glandular) part which develops from the ectoderm.

**N.B:** (1) the seminal vesicle develops as a diverticulum from the lower end of the vas (mesonephric duct). The part distal to it becomes the ejaculatory duct.

(2) the prostate gland: develops as multiple (15-20) outgrowths (buds) from the lining of the prostatic urethra which become canalized to form the alveoli & ducts of the gland. The C.T & Capsule are derived from surrounding mesoderm.





(1) the vesico-urethral canal develops into the urinary bladder & the whole urethra.

(2) the definitive urogenital sinus develops into the lower  $\frac{1}{5}$  of the vagina & its vestibule.

**N.B:** the upper  $\frac{4}{5}$  of the vagina develops from the uterovaginal canal (see page 55).

The union between the upper  $\frac{4}{5}$  & the lower  $\frac{1}{5}$  of vagina is demarcated by the hymen.

## The Urachus

it is a tubular structure extending from the apex of the urinary bladder to the umbilicus (the remnant of the allantois). It becomes obliterated after birth & forms the median umbilical lig.

## Congenital anomalies of the bladder & urethra

(1) Urachal Fistula: due to failure of obliteration of the urachus after birth leading to dripping of urine from the umbilicus.

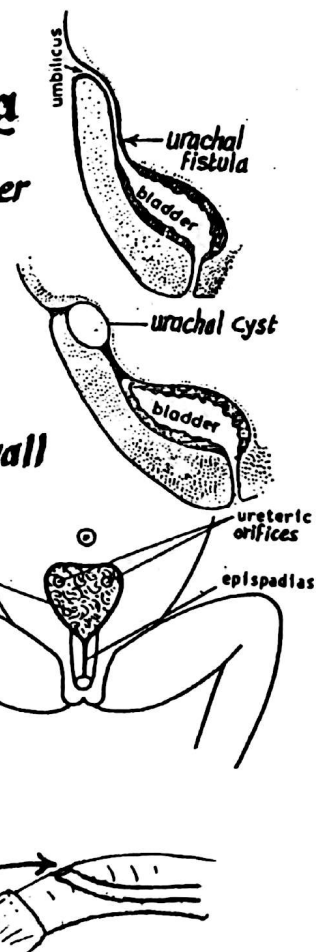
(2) Urachal cyst: due to incomplete obliteration of the urachus an intra-abdominal cyst may develop from this unobliterated part

(3) Ectopia Vesica: the urinary bladder opens into the ant.-abd. wall

where the lower part of the ant.-abd. wall is occupied by an oval area of bladder mucosa on which the 2 ureters open

(4) Hypospadias: the external urethral meatus appears on the under surface of the penis

(5) Epispadias: the external urethral meatus appears on the dorsal surface of the penis



# DEVELOPMENT OF THE GENITAL SYSTEM

58

## 1- GONADS ( TESTIS & OVARY)

### (I) THE INDIFFERENT GONAD :

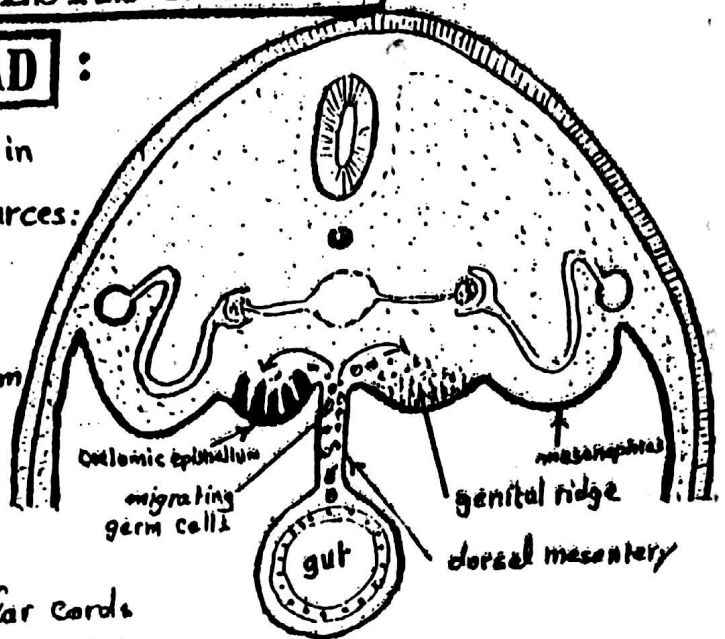
The indifferent gonad (i.e. similar in both sexes) develops from 3 sources:

(1) the genital ridge : lies on the medial side of the mesonephros & formed of the intermediate mesoderm. It gives the stroma of the gonad.

(2) the coelomic epithelium : covering the genital ridge (mesodermal)

multiplies & forms irregular cellular cords called primitive sex cords of the indifferent gonad.

(3) the primordial germ cells : (endodermal) : appear in the wall of the yolk sac & migrate along the dorsal mesentery to reach the gonadal ridge & lie in between the primitive sex cords.



### (II) DIFFERENTIATION OF THE INDIFFERENT GONAD

#### (A) FORMATION OF THE TESTIS

in the male embryo, the indifferent gonad differentiates into testis as follows:

(1) The primitive sex cords branch & anastomose forming testis cords

(2) The primordial germ cells become incorporated in the branching testis cords.

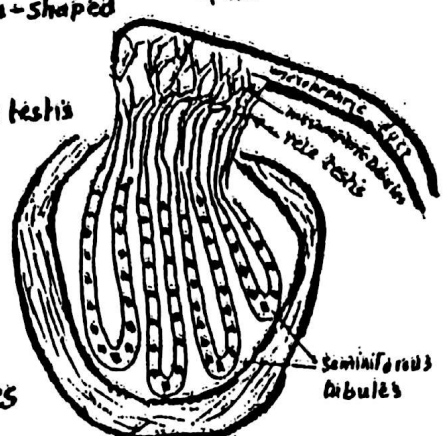
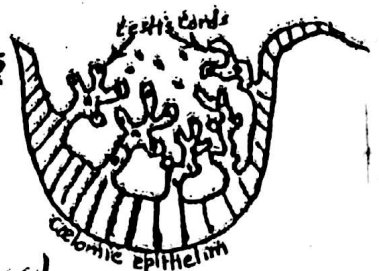
(3) The testis cords lose their connection with the surface epithelium and form the seminiferous tubules which are horse-shoe-shaped with straight ends called straight tubules.

(4) The straight tubules anastomose together at the hilum of the testis forming the rete testis

(5) The rete testis, which becomes connected to the mesonephric duct by 8-12 convoluted mesonephric tubules called Vasa efferentia, will form the head of the epididymis

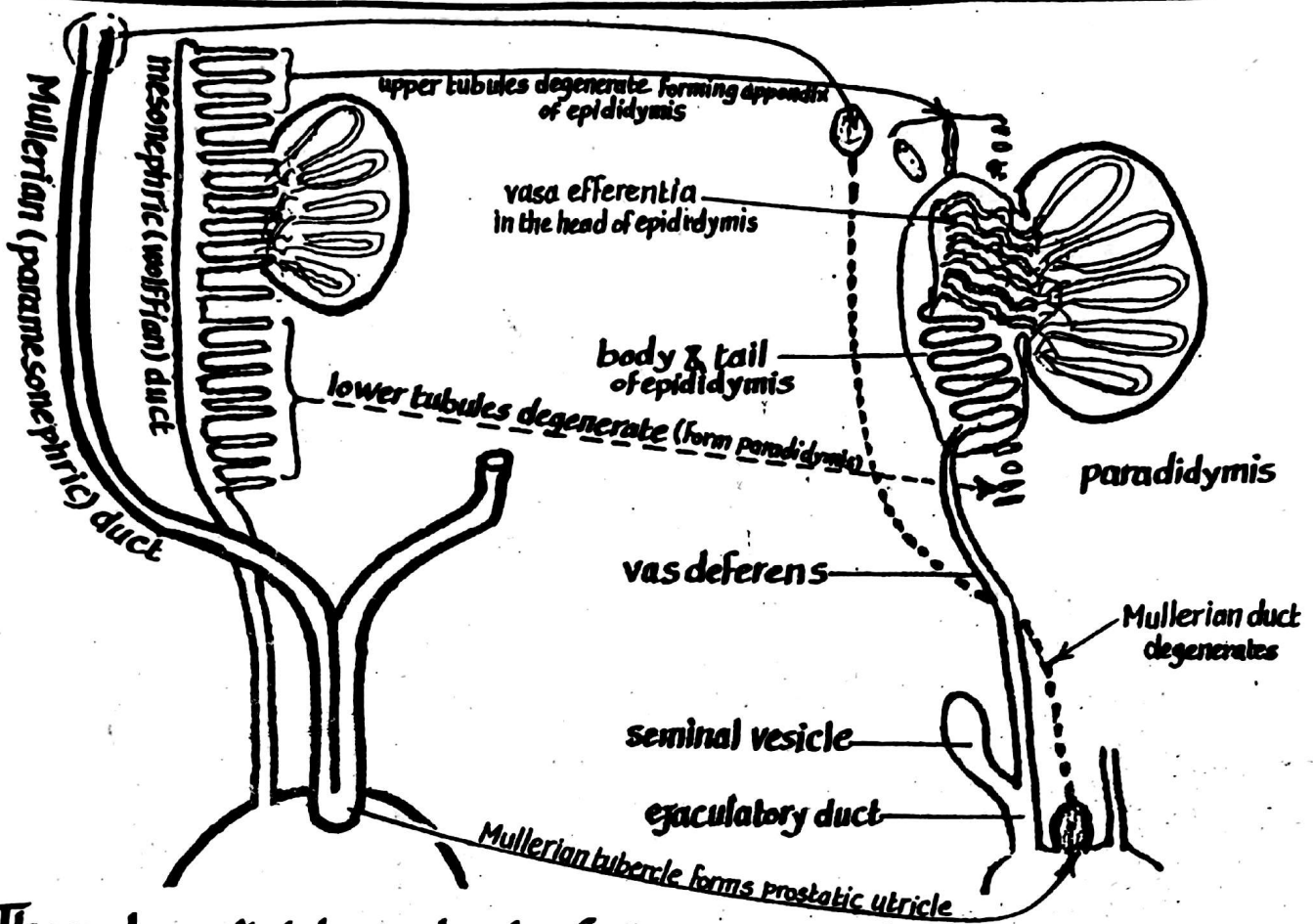
(6) The surface epithelium disappears & the testis becomes

surrounded by a thick fibrous capsule called tunica albuginea



## (B) DEVELOPMENT OF THE MALE GENITAL DUCTS 59

(epididymis, vas deferens, seminal vesicle & ejaculatory duct).



\* The male genital ducts develop from the mesonephros as follows:

- (1) the excretory mesonephric tubules adjoining the developing testis (6-12 tubules) will form the vasa efferentia (head of the epididymis) & become connected to the rete testis. The remaining mesonephric tubules above these vasa efferentia will degenerate forming appendix of epididymis while those below the testis will degenerate forming the paradidymis.
- (2) the Mesonephric (Wolffian) duct : differentiates into the following :
  - (a) the part below vasa efferentia becomes highly convoluted to form body & tail of epididymis
  - (b) the part next to the tail of epididymis will acquire a very thick muscular wall and becomes the vas deferens
  - (c) the lower part of the mesonephric duct gives out a pouch which forms the seminal vesicle.
  - (d) the lower end " " " " below seminal vesicle will become the ejaculatory duct.
- (3) the Mullerian (paramesonephric) duct degenerates completely in the male except :
  - (a) its upper end which gives the appendix of testis
  - (b) " lower " " " " prostatic utricle

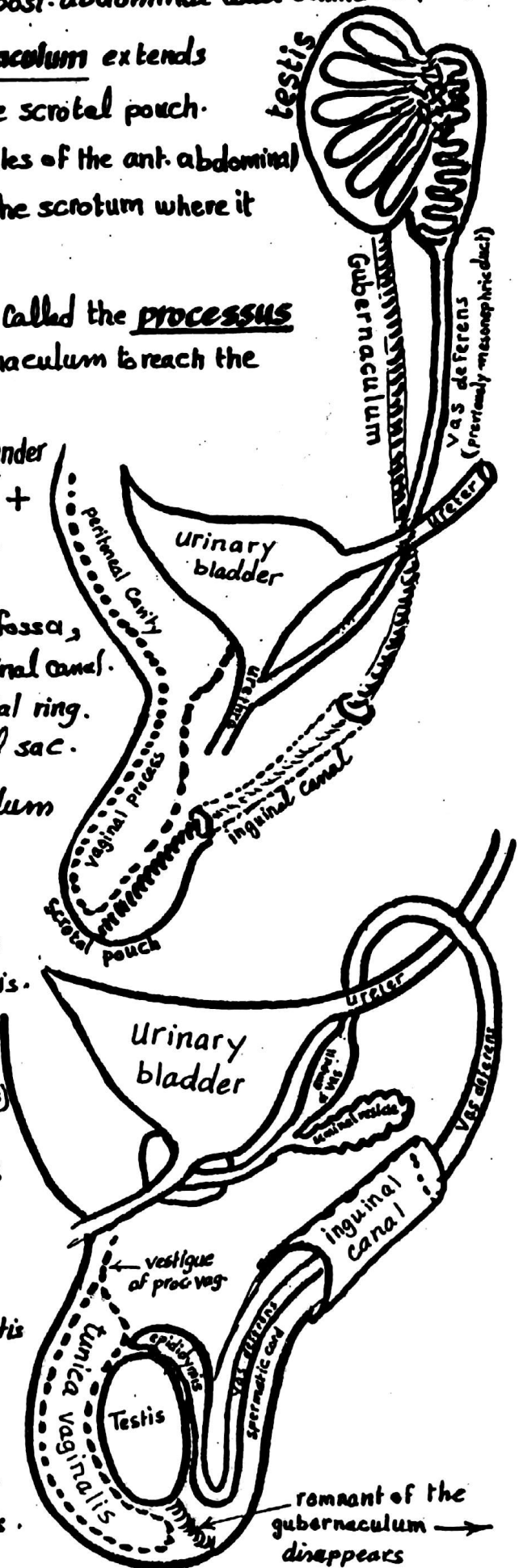
## (C) DESCENT OF THE TESTIS

60

- (1) The testis develops high up on the post-abdominal wall behind the peritoneum.
- (2) A Fibromuscular band called gubernaculum extends from the lower pole of the testis to the scrotal pouch.
- (3) The gubernaculum traverses the muscles of the ant. abdominal wall (in the inguinal canal) to reach the scrotum where it becomes attached to its bottom.
- (4) An evagination of the peritoneal sac called the processus vaginalis will accompany the gubernaculum to reach the scrotum.
- (5) Shortening of the gubernaculum under the effect of the chorionic gonadotropins + the increased intra-abdominal pressure will help dragging down of the testis :
  - at the 3rd month it lies in the iliac fossa,
  - " 7th " " " traverses the inguinal canal.
  - " 8th " " " reaches the superficial ring.
  - " 9th " " " enters the scrotal sac.
- (6) the remaining part of the gubernaculum disappears completely.
- (7) the part of the processus vaginalis inside the scrotum will form a serous cavity for the testis called tunica vaginalis.
- (8) the proximal part of the processus vaginalis becomes obliterated (vestige of processus vaginalis)

### ANOMALIES OF THE TESTIS :

- (1) Cryptorchism: failure of descent of the testis (undescended testis).
- (2) Maldescended testis: descent of the testis to an abnormal position e.g perineum, root of the penis or the femoral triangle
- (3) Congenital inguinal hernia: due to failure of obliteration of the processus vaginalis.



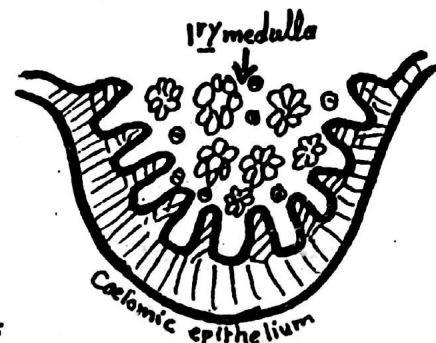
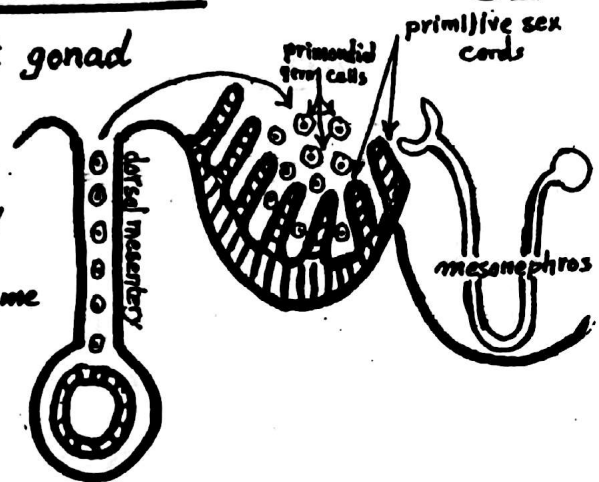


# FORMATION OF THE OVARY

61

The Ovary develops from the indifferent gonad as follows:

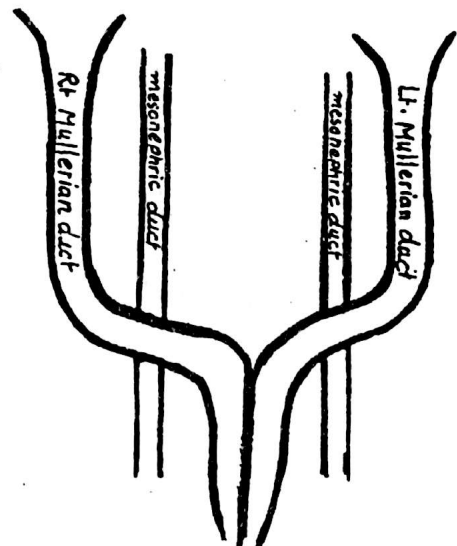
- (1) The primitive sex cords of the indifferent gonad break up into clusters of cells called the primary medullary cords which become replaced later by vascular stroma to form the medulla of the ovary
- (2) The Coelomic epithelium proliferates to form a second generation of ovary cords which divide into isolated clusters of cells. Each cell cluster will form the follicular cells of a primary follicle
- (3) The primordial germ cells (endodermal, from the yolk sac) will be incorporated into the clusters and give rise to oogonia
- (4) the primitive cortex is thus transformed into the 2<sup>ry</sup> or permanent cortex containing the primary follicles (cell clusters containing oogonia)



## DEVELOPMENT OF THE FEMALE GENITAL DUCTS

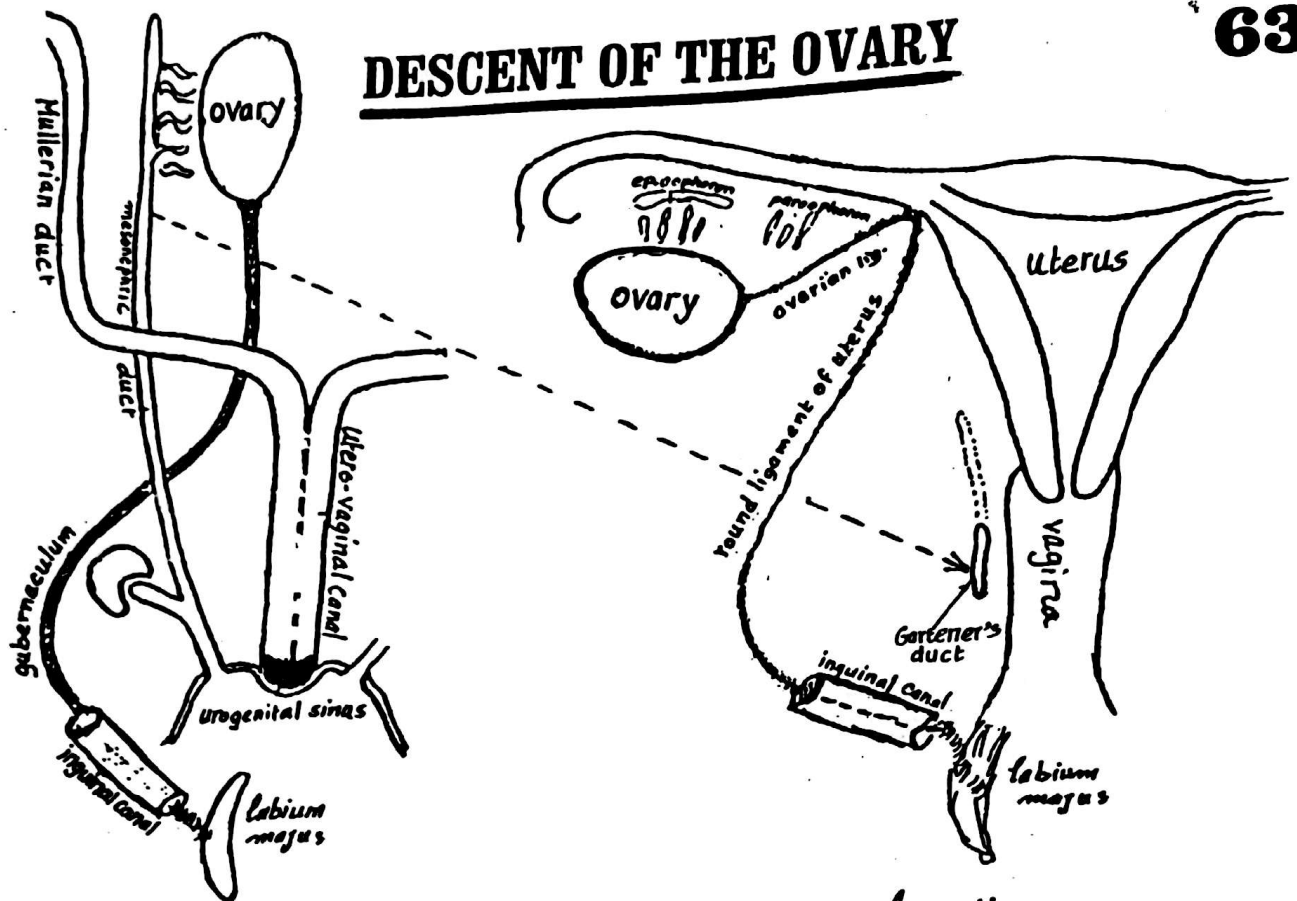
The female genital ducts develop from the Mullerian (paramesonephric) ducts as follows:

- (1) the Mullerian (paramesonephric) ducts arise as 2 longitudinal invaginations of the Coelomic epithelium lateral to the mesonephric ducts.
- (2) each mullerian duct curves medially in front of the mesonephric duct then bends caudally separated by a septum from the opposite Mullerian duct.





## DESCENT OF THE OVARY



- (1) The ovary develops high up on the post. abdominal wall.
- (2) A Fibromuscular band called the gubernaculum ovarii extends from the lower pole of the ovary, traverses the inguinal canal to get attached to the labium majus.
- (3) Contraction of the gubernaculum pulls the ovary from its high abdominal position to its lower level in the pelvis.
- (4) the development of the uterus divides the gubernaculum into 2 parts :
  - (a) an upper part extending between the ovary & the uterus (called ovarian lig.).
  - (b) a lower " " " the uterus & the labium majus called the round lig. of the uterus.

### \* Congenital anomalies of the ovary:

- (1) congenital absence (Agenesis) leading to Turner's syndrome
- (2) true hermaphroditism : the gonads of both sexes are present in the same person (ovotestis).
- (3) Accessory ovarian tissue : may be found along the course of migration of the ovary
- (4) imperfect descent : the ovary may fail to descend to the pelvis or rarely may be pulled by the round lig. to the inguinal canal.

## (A) - Anomalies due to failure of fusion of the 2 Mullerian ducts

- (1) Double uterus & double vagina : due to complete failure of fusion of the right & left Mullerian ducts
- (2) Double uterus & single Vagina : due to partial failure of fusion of the 2 Mullerian ducts.
- (3) Bipartite uterus : a small septum remains in the upper part of the uterine cavity.
- (4) Arcuate uterus : the fundus is slightly depressed due to minor degree of imperfect fusion of the 2 Mullerian ducts.



## (B) Anomalies due to Complete or partial atresia of one or both Mullerian ducts:

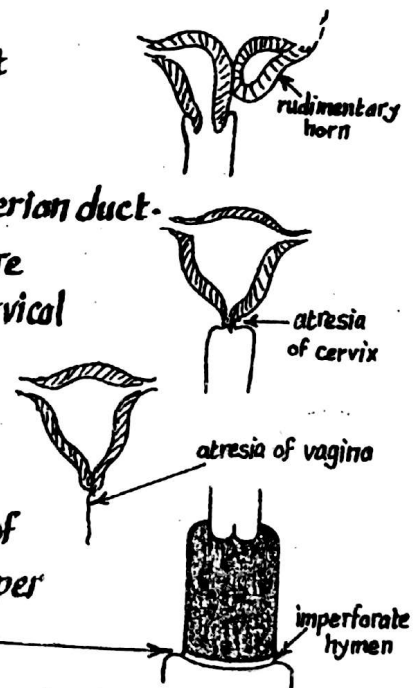
(1) Agenesis of uterus : a rare condition due to failure of development of the 2 Mullerian ducts.

(2) Rudimentary horn : due to failure of one Mullerian duct to develop leaving one uterine tube &  $\frac{1}{2}$  of the body of the uterus connected to a rudimentary horn of the opposite Mullerian duct.

(3) Atresia of cervix : due to failure of the cells in the centre of the cervix to degenerate to form cervical canal.

(4) Atresia of vagina : due to atresia of the lower ends of Mullerian ducts.

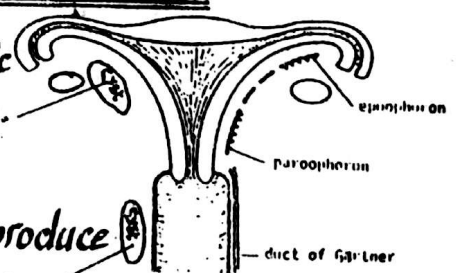
(5) Imperforate hymen : due to failure of degeneration of the cells at the junction between the upper  $\frac{4}{5}$  & the lower  $\frac{1}{5}$  of the vagina.



## C - Anomalies due to remnants of the Mesonephric duct in the female

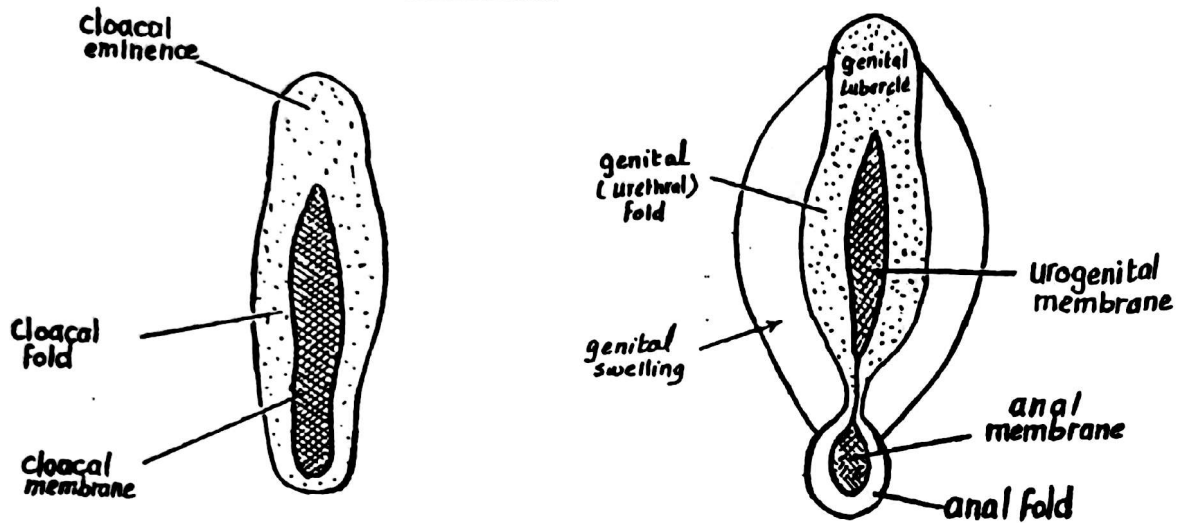
(1) The epoophoron & paroophoron (remnants of mesonephric tubules) may enlarge and form cysts in the broad lig. of the uterus.

(2) Gartner's duct (remnant of mesonephric duct) may produce a cyst (Gartner's cyst) located alongside the vagina.





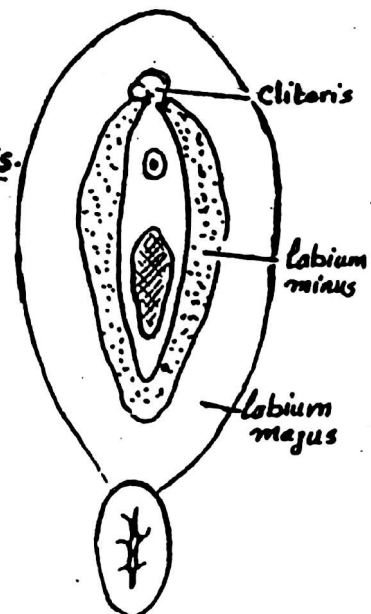
## I- The indifferent stage:



- (1) In the early stages of development the external genitalia are identical in both males & females & represented by 2 mesenchymal swellings called Cloacal folds on each side of the Cloacal membrane.
- (2) The 2 Cloacal folds fuse with each other in front of the Cloacal membrane to form the Cloacal eminence which will enlarge to form the genital tubercle.
- (3) The Cloacal membrane divides into urogenital & anal membranes
- (4) At the same time, the cloacal folds also divide into genital (urethral) folds in front & anal folds behind.
- (5) Another pair of elevations called the genital swellings are formed on either side of the genital folds.

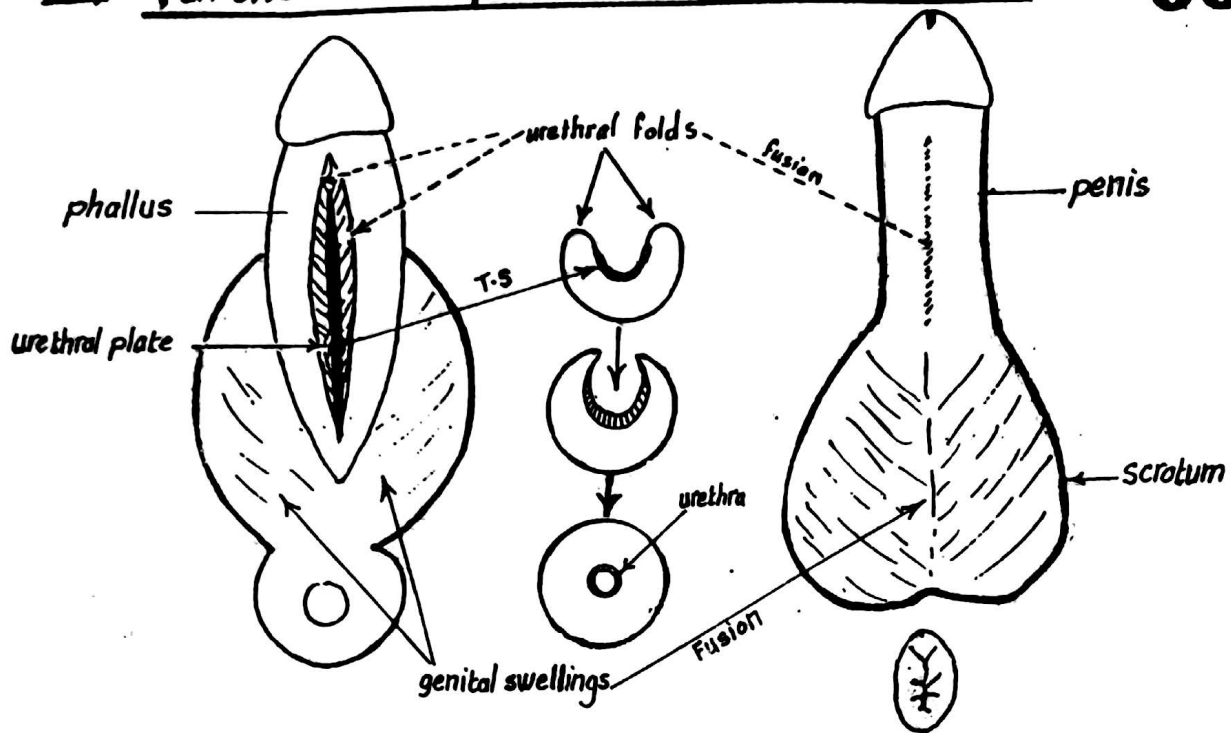
## II- Further development in the female embryo:

- (1) the genital tubercle enlarges slightly to form the clitoris.
- (2) the genital (urethral) folds do not fuse but remain separated forming labia minora.
- (3) the genital swellings will enlarge greatly to form the 2 labia majora.



### III- Further development in the male embryo

66



- (1) the genital tubercle : elongates greatly to form the **phallus** (penis)
- (2) the genital folds : are pulled by the elongated phallus to form the lat. edges of a deep groove called the urethral groove which extends along the caudal aspect of the elongated phallus.
  - the endoderm at the bottom of the urethral groove will form the urethral plate.
  - At the end of the 3<sup>rd</sup> month the 2 urethral folds fuse & close over the urethral plate forming the urethral canal.
  - the distal part of the urethra is derived from the ectoderm.

- (3) the genital swellings: will form 2 scrotal swellings which will fuse together forming the scrotum.

#### \* Congenital anomalies :

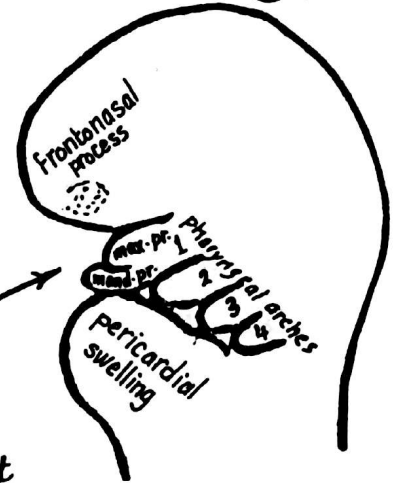
- (1) **Absence of penis or clitoris** : due to failure of development of genital tubercle.
- (2) **Small penis** : due to underdevelopment of genital tubercle in the male
- (3) **large clitoris** : " " overdevelopment " " " " female } common in hermaphrodites
- (4) **divided scrotum** : due to failure of fusion of the genital swellings in the male.
- (5) **false hermaphrodite** : the external genitalia belong to one sex while the gonads belong to the opposite sex.

# Development of the Face

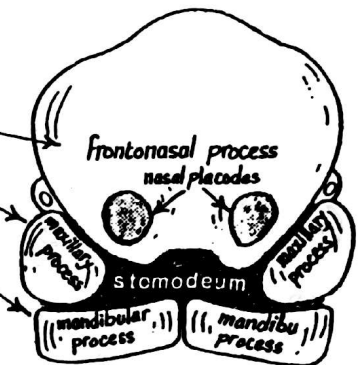
67

## I- Formation of 5 processes around the stomodeum:

- (1) the upper part of the head fold projects downwards & forwards to form the frontonasal process.
- (2) the pericardial swelling projects upwards
- (3) a depression called the stomodeum (primitive mouth) is formed between the previous 2 swellings
- (4) pharyngeal arches appear on either side of the pharyngeal gut
- (5) the 1<sup>st</sup> pharyngeal arch develops 2 processes → mandibular process ventrally.  
→ maxillary process dorsally.
- (6) the stomodeum becomes surrounded by 5 processes:



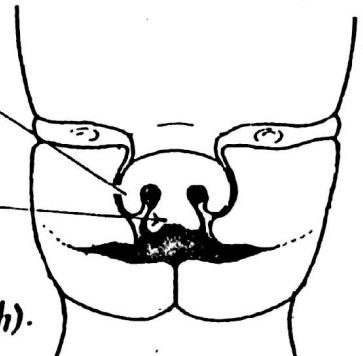
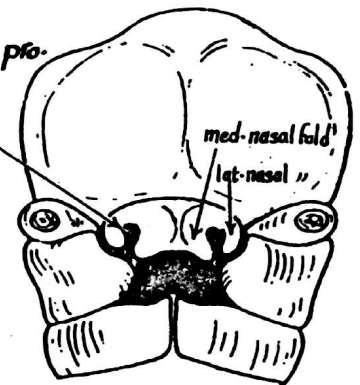
- frontonasal process ----- craniully
- 2 maxillary processes ----- on each side
- 2 mandibular processes ----- caudally



## II- Differentiation & fusion of the 5 processes:

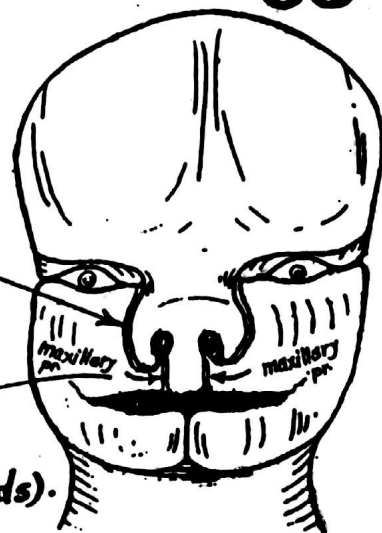
### (A) The Fronto-nasal process:

- (1) 2 nasal placodes (buds) develop on either side of the frontonasal pro.
- (2) each nasal placode becomes invaginated to form a nasal pit.
- (3) the edges of each nasal pit form med- & lat- nasal folds.
- (4) the nasal pits become deeper forming the nasal cavities which will later open into the pharynx posteriorly.
- (5) each lat-nasal fold will form the ala of the nose
- (6) the 2 med-nasal folds unite together:
  - (a) on the surface: to form the middle part of the nose & the filtrum of the upper lip
  - (b) at a deeper level: to form the premaxilla which includes
    - the ant-part of the upper jaw (Carrying the incisor teeth).
    - the primary palate (the ant- triangular part of the palate carrying the incisive fossa).



## (B) the 2 maxillary processes:

- (1) each maxillary process grows medially and approaches the med. & lat. nasal folds but remains separated from them by nasolacrimal groove which later will form the nasolacrimal duct
- (2) the 2 maxillary processes fuse with the medial nasal folds of the frontonasal process to form the upper lip (except the Filtrum which is formed by fusion of the 2 med. nasal folds).



- (3) each maxillary process unites :

- (a) anteriorly: with the lat. nasal fold along the side of the nose
- (b) posteriorly: with the mandibular process to form the cheek

## (C) the 2 mandibular processes:

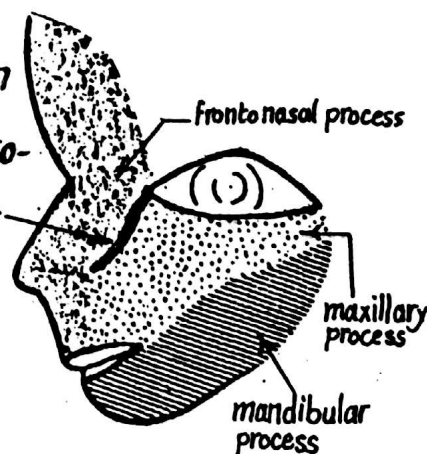
- (1) they fuse above with the maxillary process forming the cheeks.
- (2) they fuse with each other medially to form the lower lip & chin.



### N.B:

- (1) the degree of fusion between the maxillary & mandibular processes determines the width of the mouth.

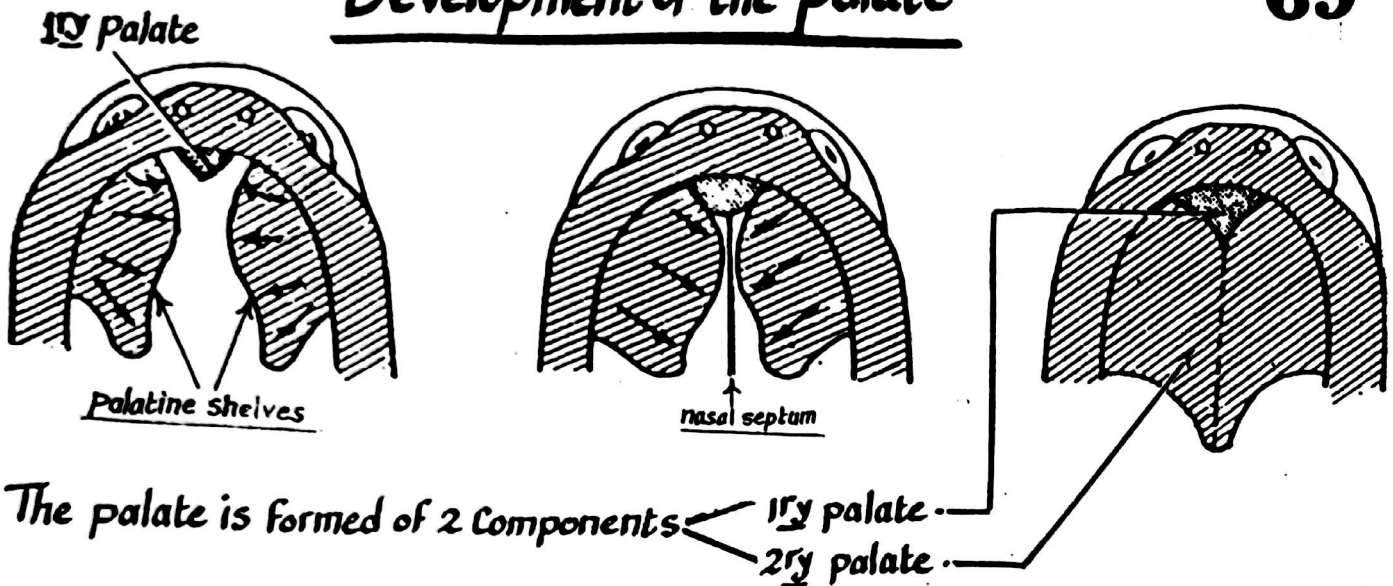
- (2) the Nasolacrimal duct develops at the line of fusion between the maxillary & frontonasal processes (at the nasolacrimal groove) as a solid cord which becomes canalized. The lids & Conjunctival sac appear at the upper end of the nasolacrimal duct.





# Development of the palate

69



The palate is formed of 2 Components

## (1) The primary palate:

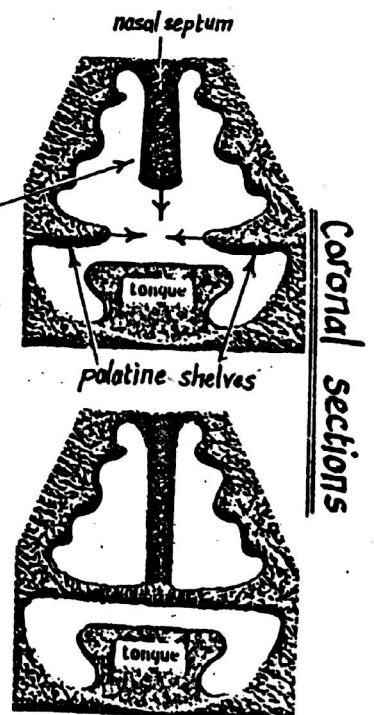
- \* it is the small ant.-triangular part of the palate which carries the incisive fossa.
- \* it develops from the intermaxillary segment of the frontonasal process (which is formed by fusion of the 2 med. nasal folds at a deep plane).

## (2) The Secondary palate:

- \* it is the remaining large part of the palate.
- \* it is formed by 2 shelf-like processes called the palatine shelves which arise from the maxillary processes.
- \* the 2 palatine shelves grow medially & forwards to fuse:
  - (a) with each other in the middle line &
  - (b) with the 1<sup>st</sup> palate anteriorly (in a V-shaped manner).

(3) The nasal septum descends vertically downwards from the frontonasal process to fuse with the upper surface of the palate in the middle line.

(4) Ossification occurs in the ant. part of the palate forming the bony palate while the post. part remains fleshy & forms the soft palate.

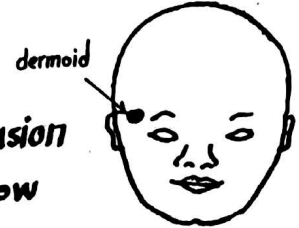


# Congenital anomalies of the face & palate

70

## (1) Inclusion dermoid (dermoid = skin-like) :

it is a cystic swelling which may be found along the lines of fusion of the face. The commonest site is the lat-end of the upper eye brow (called external angular dermoid).




## (2) Macrostomia (large mouth) :

It is due to incomplete fusion between the maxillary & mandibular processes (too little closure of the stomodeum).



## (3) Microstomia: (small mouth)

due to excessive fusion between the maxillary & mandibular processes leading to great closure of the stomodeum.




## (4) Oblique facial cleft :

it is a rare condition resulting from failure of fusion between the maxillary process & frontonasal process. There is a cleft lip which extends along the side of the nose to reach the med. angle of the eye.



## (5) Lateral cleft upper lip (hare lip) :

it is due to failure of fusion between the maxillary process & the filtrum (of frontonasal process). It may occur on one side (unilateral cleft lip) or on both sides (bilateral cleft lip).



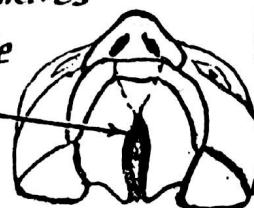## (6) Cleft palate : due to failure of fusion between the different segments of the palate. It may be partial or complete, unilateral or bilateral :

(a) unilateral complete cleft palate : a cleft runs between the 2 palatine shelves then between the premaxilla & one palatine shelf.

(b) bilateral complete cleft palate : the cleft between the 2 palatine shelves extends anteriorly in a V-shaped manner separating the premaxilla from the 2 palatine shelves

(c) partial cleft palate : may affect the soft palate alone or extends to the post-part of hard palate.

(d) cleft uvula : the cleft affects the uvula alone.

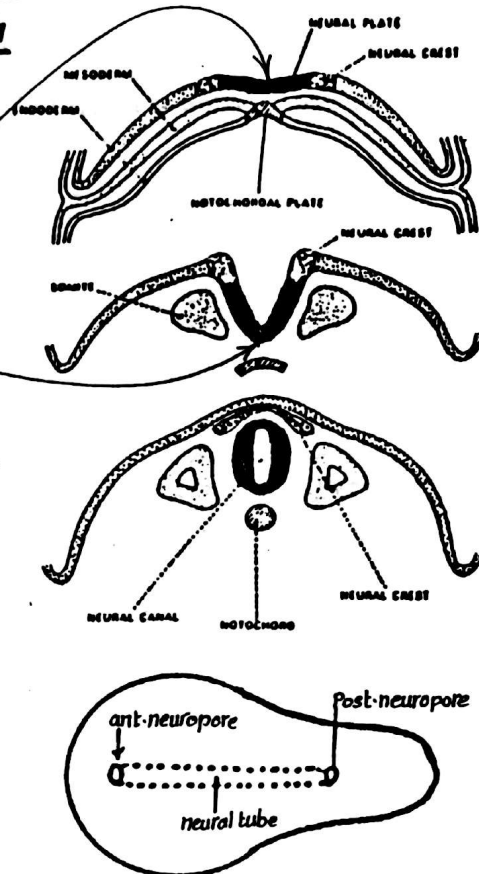


# DEVELOPMENT OF THE CENTRAL NERVOUS SYSTEM

71

\* the C.N.S develops from the Neural tube which arises from the ectoderm as follows:

- It appears in the 3<sup>rd</sup> week as a thickening of the ectoderm known as the Neural plate extending from the prochordal plate in front to the caudal end of the embryonic disc behind
- The neural plate will form the Neural groove which has 2 elevated edges called the neural folds
- The neural folds fuse together transforming the neural groove into Neural tube lying beneath the ectoderm in the median plane.
- The fusion of the folds is absent at the ant. & post. ends of the tube leaving 2 openings on the ectoderm called the ant. & the post. neuropores.
- Later on, the ant. neuropore closes at the 23<sup>rd</sup> day while the post. neuropore closes at the 25<sup>th</sup> day.

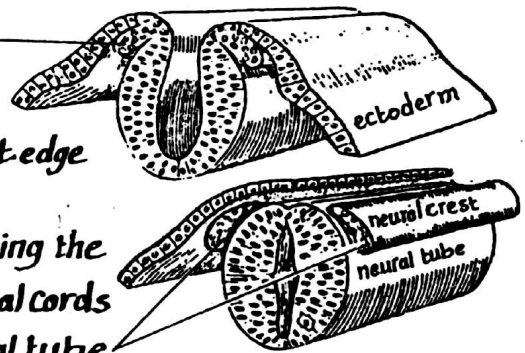


\* The closed neural tube develops into the spinal cord & the brain

## THE NEURAL CREST

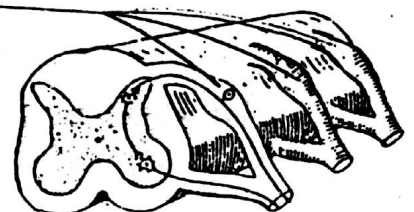
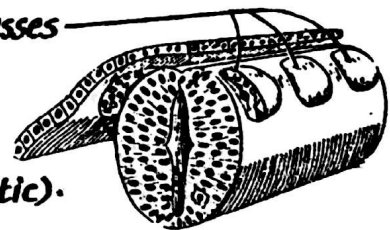
\* Formation:

- it arises as a strip of ectodermal cells situated along the lat. edge of the neural groove
- As the 2 edges of the neural groove fuse together forming the neural tube, the 2 neural crests separate as 2 longitudinal cords that migrate ventrally to lie one on each side of the neural tube



\* Derivatives: the neural crest becomes segmented into masses which give the following derivatives:

- (1) Sensory ganglia of the cranial nerves (5, 7, 9 & 10).
- (2) Autonomic ganglia (both sympathetic & parasympathetic).
- (3) dorsal root ganglia of all spinal nerves.
- (4) neurilemmal (Schwann) cells of peripheral nerves.
- (5) the medulla of the suprarenal gland (chromaffin cells).
- (6) melanoblasts of the skin which produce melanin pigment.
- (7) Arachnoid & pia mater which are ectodermal (but not the dura mater which is mesodermal).



# DEVELOPMENT OF THE SPINAL CORD

72

The Spinal cord develops from the caudal part of the neural tube as follows :-

(1) At first, the neural tube is formed of one layer of simple columnar epithelium surrounding an oval central canal.

(2) Later on, this layer proliferates & the neural tube becomes formed of 2 thick lat. walls connected by a thin roof plate & a thin floor plate.

(3) The lat. walls differentiates into 3 layers :

(a) Inner ependymal layer : the cells of which gives rise to  
 - the ependymal cells lining the central canal of the spinal cord.  
 - the primitive nerve cells (neuroblasts) which migrate to the mantle layer.

(b) Middle mantle layer : formed of nerve cells (neuroblasts) & neuroglial cells (spongioblasts) which form the grey matter

(c) Outer marginal layer : formed of nerve fibres (ascending & descending tracts) which constitute the white matter

(4) a groove called sulcus limitans appears on the inner surface of the lat. wall on either side dividing it into

(a) an alar plate posteriorly which contains sensory cells and forms the post. horn of the spinal cord.

(b) a basal plate anteriorly, contains motor cells & forms the ant. horn of the spinal cord.

(5) enlargements are formed in the cervical & lumbar regions of the spinal cord & the central canal becomes narrow.

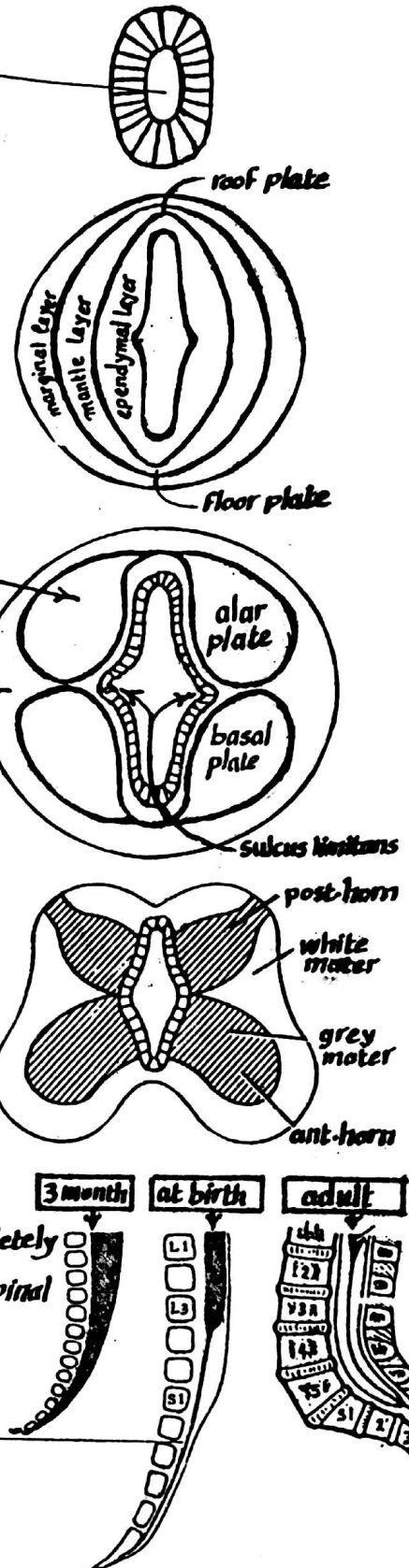
(6) Growth of the spinal cord :

- till the 3<sup>rd</sup> month the spinal cord fills the vertebral canal completely  
 - the vertebral column then grows at a faster rate than the spinal cord producing the following changes :

(a) the caudal end of the cord is overstretched forming the filum terminal

(b) the lower end of the cord shifts upwards to lie at the level of L3 at the time of birth

(N.B) In the adult, the spinal cord ends at the disc between L1 & L2





(7) Myelination of the nerve fibres in the spinal cord begins in the 4<sup>th</sup> month of intrauterine life & is completed by the end of the 1<sup>st</sup> year of post natal life.

(8) development of the spinal meninges :

(a) the dura mater : develops from the mesoderm of the sclerotomes which form the vertebral column.

(b) the arachnoid & pia mater : develop from the neural crest (ectodermal in origin).

### Congenital anomalies of the Spinal cord

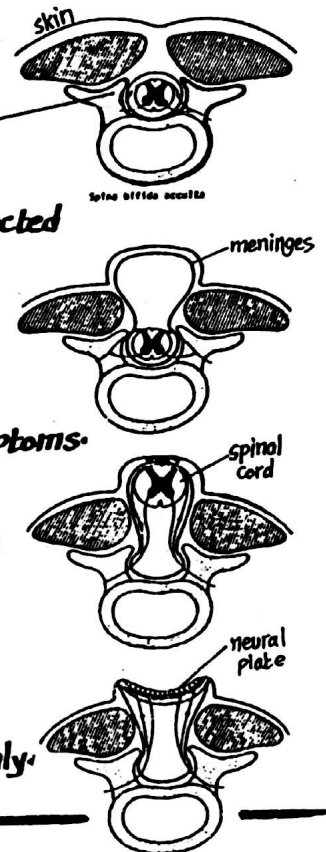
(1) Spina bifida occulta : due to failure of fusion of the dorsal parts of one of the vertebrae around the spinal cord (which is normal)

This condition occurs commonly in the lumbosacral region & the affected site is covered by hairy skin.

(2) Meningo cele : due to failure of fusion of the dorsal parts of 2 or 3 vertebrae. In this anomaly, the meninges bulge through the defect & the condition is accompanied by some neurological symptoms.

(3) Meningo-myelocele : like the previous condition but here the spinal cord bulges through the defect. This anomaly is accompanied by severe neurological manifestations.

(4) Myelocele : due to failure of closure of the neural tube & the affected part of the spinal cord remains exposed to the surface through the defect in the vertebral canal. It is the most serious anomaly.



### DEVELOPMENT OF THE BRAIN

\* The brain develops from the cranial end of the neural tube as follows

(1) the cranial end of the neural tube expands to form the brain swelling.

(2) 2 constrictions appear in the brain swelling, dividing it into 3 parts called brain vesicles :

- (a) fore brain or prosencephalon.
- (b) mid brain or mesencephalon.
- (c) hind brain or rhombencephalon.

(3) the 3 brain vesicles differentiate as follows :

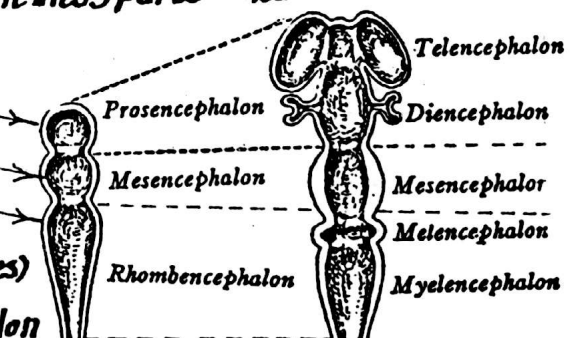
(A) The fore brain : gives 2 optic vesicles (the future eyes) then divides into :- a median part called the diencephalon

- 2 lat. diverticula called telencephalic vesicles (the future cerebral hemispheres).

(B) The mid brain : remains undivided.

(C) The hind brain : gives rise to the following derivatives :

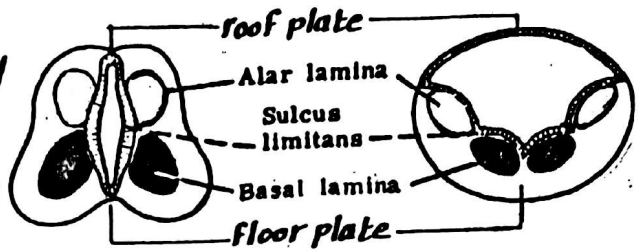
- (1) metencephalon which forms the pons & cerebellum.
- (2) myelencephalon which forms the medulla oblongata



# Development of the brain stem

74

\*As in the development of the spinal cord, the lateral walls of the brain stem are connected by a thin roof plate & a thin floor plate & will have a ventral basal lamina (containing motor nuclei) & a dorsal alar lamina (containing sensory nuclei).



Each wall shows a sulcus limitans internally, separating the alar lamina from the basal lamina.

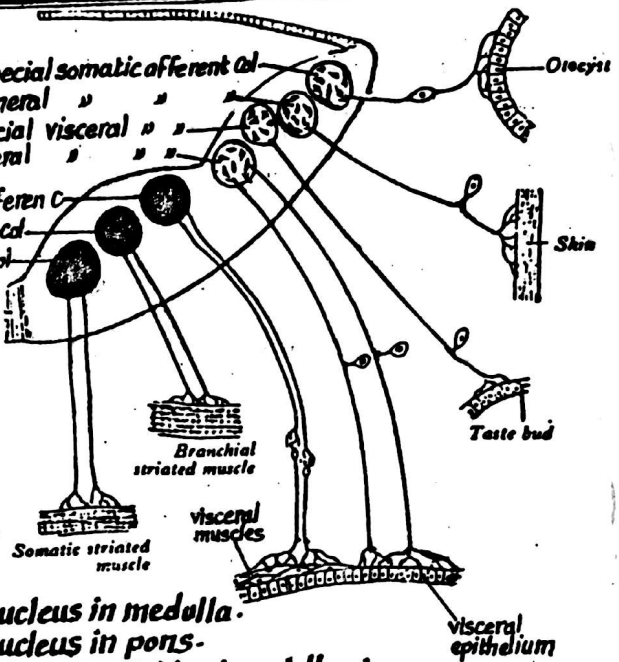
## \*Differentiation of the basal & alar laminae into Columns of Nuclei:

- the alar lamina differentiate into 4 columns of sensory nuclei
- the basal lamina differentiates into 3 columns of motor nuclei

### (A) Columns of the Basal lamina:

#### (1) Somatic efferent column: (most medial)

- it lies close to the middle line, in line with the Ant-horn cells of the spinal cord.
- its efferent fibres supply somatic striated muscles (i.e derived from the somites).
- it differentiates into the following nuclei:
  - 12th n. nucleus in medulla.
  - 6th n. nucleus in pons.
  - 3rd & 4th nn. nuclei in the midbrain.



#### (2) Special Visceral (branchial) efferent column:

- it lies just lateral to the somatic efferent column.
- its efferent fibres supply the muscles derived from the branchial (pharyngeal) arches.
- it differentiates into the following nuclei:
  - 5th & 7th nerves motor nuclei: in the pons.
  - 9th, 10th & 11th nerve motor n.: in the medulla (which join together forming nucleus ambiguus).

#### (3) General Visceral efferent column:

- lies just lat. to the special visceral efferent column, in line with autonomic lat-horn grey matter of the spinal cord.
- its efferent fibres are parasympathetic supplying visceral smooth muscles & glands
- it differentiates into the following nuclei:
  - (1) dorsal nucleus of vagus: in the medulla
  - (2) inf. salivary nucleus (of glossopharyngeal n.): in the medulla
  - (3) sup. salivary nucleus (of facial n.): in the pons
  - (4) Edinger-Westphal nucleus (of oculomotor n.) in the midbrain.

## (B) The Columns of the Alar lamina:

the alar lamina forms 4 sensory (afferent) columns as follows:

### (1) General Visceral afferent Column:

- it is the most med. of the sensory columns.
- it receives afferent sensory fibres from the viscera.
- it is represented by the sensory component of the dorsal vagal nucleus

### (2) Special Visceral afferent column:

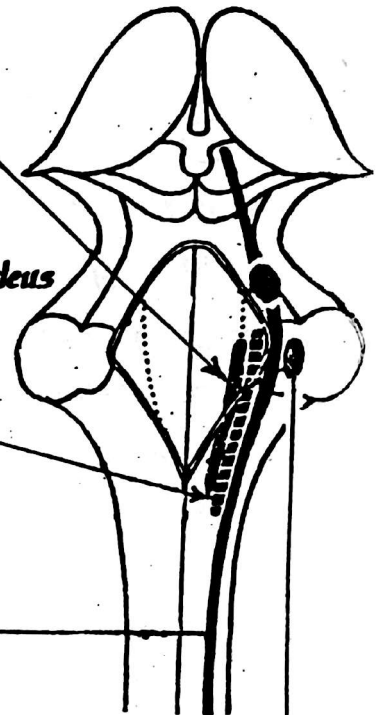
- it lies just lat. to the general visceral afferent column.
- it receives taste sensation from the tongue & epiglottis.
- it is represented by the nucleus of tractus solitarius.

### (3) General somatic afferent column:

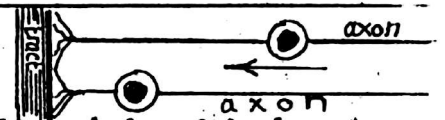
- lies lat. to the special visceral afferent column.
- it receives afferent sensory fibres from the skin of the face & scalp + proprioceptive sensation from the muscles of mastication
- this column differentiates into the 3 sensory nuclei of trigeminal n. → spinal, main sensory, mesencephalic.

### (4) Special Somatic afferent Column:

- It is the most lat. column of the alar lamina.
- it receives afferent auditory & vestibular fibres of the vestibulocochlear n.
- it is represented by the vestibular & cochlear nuclei.



## \* Migration of Nuclei (Neurobiotaxis):



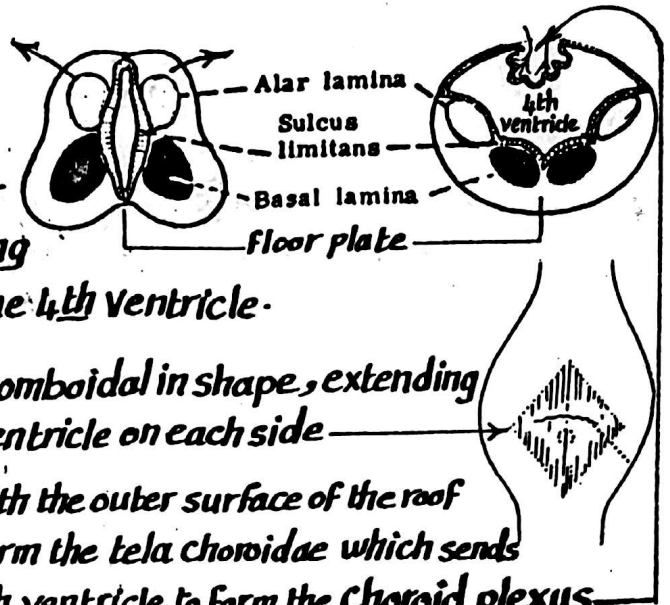
- (1) some of the motor nuclei of the cranial nerves migrate from their original position towards the chief fibre tracts from which it receives maximal impulses. This is called neurobiotaxis & is manifested by the migration of the facial motor nucleus & the vagus motor nucleus (nucleus ambiguus) resulting in bending of the axons emerging from these nuclei
- (2) Some of the nuclei of the dorsal alar lamina (mostly extrapyramidal) migrate ventrally. Examples of these nuclei are the following:
  - (a) the olivary nucleus in the medulla.
  - (b) the pontine nuclei in the pons.
  - (c) the red nucleus & substantia nigra in the midbrain.

## Development of the lumen of the brain stem

76

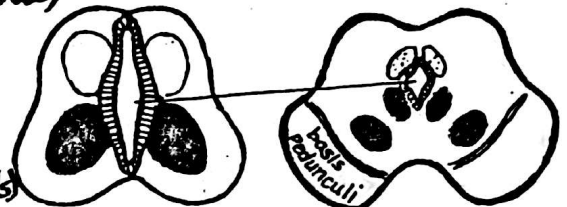
### (1) Formation of the 4<sup>th</sup> Ventricle:

- In the rhombencephalon, the alar laminae of both sides move away from each other (as in the way of opening a book) leading to widening of the lumen thus forming the 4<sup>th</sup> Ventricle.
- the thin roof plate becomes stretched & rhomboidal in shape, extending laterally to form the lat. recess of the 4<sup>th</sup> ventricle on each side
- the vascular mesenchyme lying in contact with the outer surface of the roof plate forms the pia mater & the 2 layers form the tela chorioidea which sends vascular projections into the cavity of the 4<sup>th</sup> ventricle to form the Choroid plexus
- local resorption of the roof plate leads to the formation of a median foramen (of Magend) & 2 lateral foramina (of Luschka)



### (2) Formation of the cerebral aqueduct:

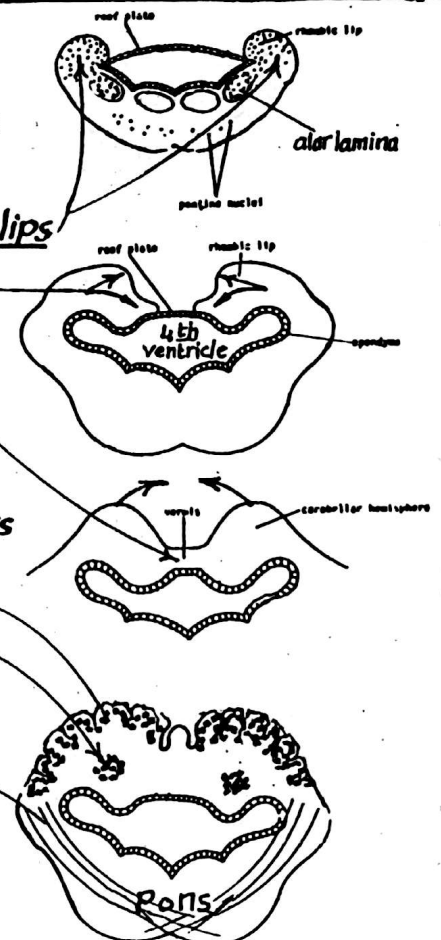
the lumen of the mesencephalon (midbrain) becomes much reduced (due to thickening in the walls) & is transformed into a central canal called the cerebral aqueduct (of sylvius)



## Development of the Cerebellum

\* The cerebellum is formed of the dorsal part of the alar laminae of the metencephalon as follows :

- (1) the alar laminae of both sides bend medially to form the rhombic lips each of which grows to form medial & lateral bulges
- (2) the med. bulges of both sides meet each other over the roof plate of the 4<sup>th</sup> ventricle & unite forming the vermis
- (3) the lat. bulges grow to form the cerebellar hemispheres
- (4) the cerebellar cortex is formed by migration of neuroblasts from the mantle layer to enter the marginal layer
- (5) the dentate nucleus develops as a collection of neuroblasts which remains deeply situated in the mantle layer.
- (6) the cerebellar peduncles develop later as the axons of the neurones of the cerebellar nuclei grow out of the cerebellum to reach the brain stem.





# Development of the forebrain (prosencephalon)

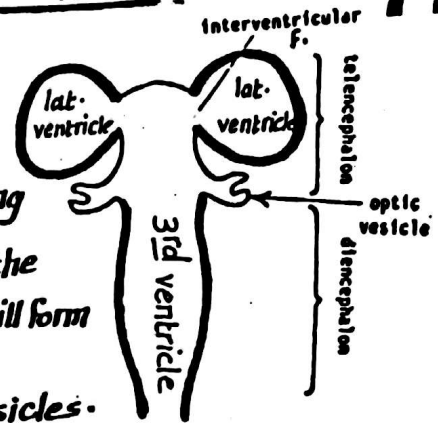
77

\* It is the most cranial of the 3 brain vesicles.

\* a lat. diverticulum appears on each side of the forebrain (called the optic vesicle) subdividing the forebrain into:

(a) Telencephalon: the cranial part of the forebrain, including the 2 lat. diverticula. It gives 2 lat. outpocketings forming the Cerebral hemispheres while each optic vesicle & its stalk will form the retina & optic n.

(b) Diencephalon: the part immediately caudal to the optic vesicles. It develops into the thalamus, hypothalamus, epithalamus & pineal body.



## Development of the Cerebral hemispheres

\* The 2 cerebral hemispheres arise as 2 evaginations from the lat. wall of the forebrain (prosencephalon).

\* the cavity of each evagination expands forming lat. ventricle

\* the wall of each hemisphere is formed of the following layers:

(a) outer marginal layer formed of white matter

(b) middle mantle layer formed of nerve cells (neuroblasts)

(c) inner ependymal layer lining the cavity of the lat. ventricle

\* As development proceeds the following changes occur:

(1) the neuroblasts of the wall of the hemisphere (except its base) migrate from the mantle layer to the marginal layer forming the grey matter of the cortex

& the axons of these neuroblasts invade the rest of the wall forming the white matter of the cerebral hemisphere

(2) the neuroblasts of the mantle layer at the base of the hemisphere do not migrate to the marginal layer but remain deeply situated forming masses of grey matter (Corpus striatum)

(3) the part of the med. wall of the hemisphere just above the roof of the 3rd ventricle is invaginated by choroid plexus forming the choroid fissure

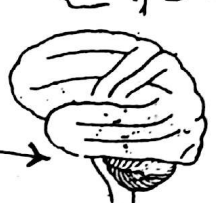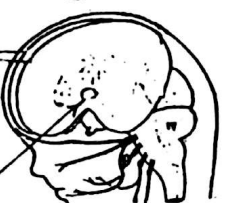
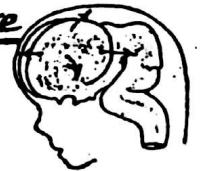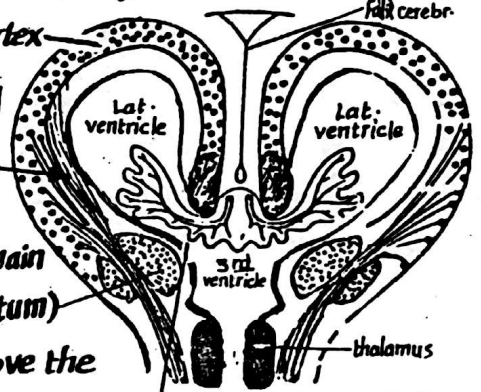
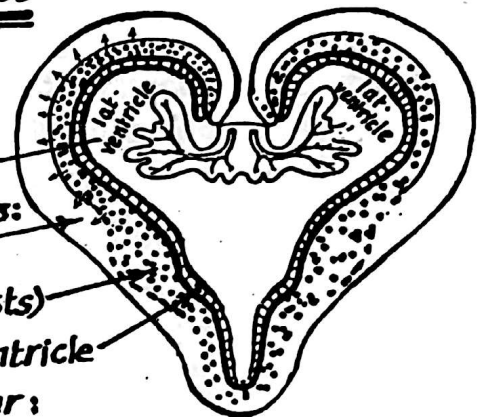
(4) Expansion of the cerebral cortex: the cortex expands in all directions → resulting in the following changes:

(a) the med. surfaces of the 2 hemispheres come very close to each other.

(b) the corpus striatum at the base of the hemisphere is pushed towards the thalamus but kept separated from it by the fibers of the internal capsule.

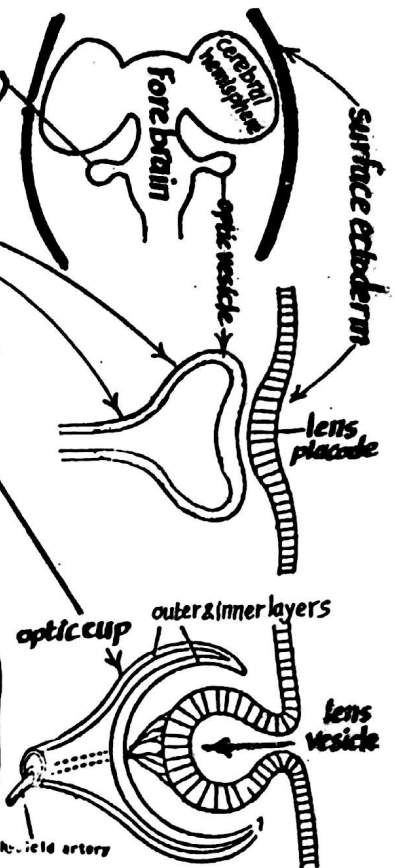
(c) the insula which appears on the lat. surface as an area of less active growth becomes buried deep to the surface by the surrounding actively growing parts

(d) the cerebral hemispheres overlap the brain stem & cerebellum



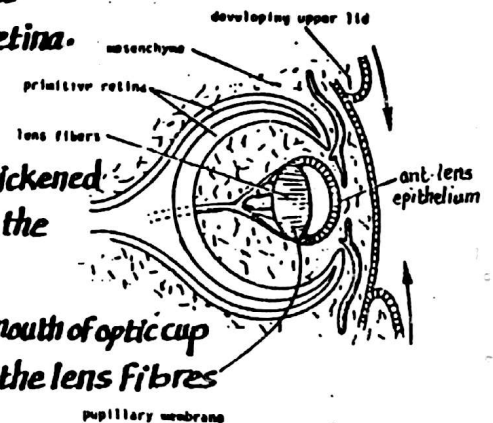
## (A) Development of the Retina & optic n.:

- (1) the optic vesicle develops as a hollow diverticulum (one on each side) from the ventrolateral aspect of the prosencephalon (forebrain).
- (2) it extends laterally, its distal blind end expands while its proximal part remains narrow forming the optic stalk.
- (3) the distal expanded end of the optic vesicle comes in contact with the surface ectoderm & becomes invaginated to form the optic cup which is formed of 2 layers :
  - (a) outer layer : forms the pigmented layer of the retina
  - (b) inner layer : differentiates as follows :
    - its ant.  $\frac{1}{5}$  forms the inner layer of the iris & ciliary body.
    - its post  $\frac{4}{5}$  forms all layers of the retina except the pigmented layer.
- (4) the mouth of the optic cup will form the pupil of the eye.
- (5) the optic stalk is invaginated inferiorly by a groove called the choroid fissure lodging the hyaloid a. which extends forwards to end in the foetal lens.
- (6) the choroid fissure becomes closed by approximation & fusion of its 2 lips around the artery. The optic stalk is thus transformed into optic nerve while the hyaloid a. becomes the central a. of retina.



## (B) Development of the lens :

- (1) the surface ectoderm opposite the developing optic cup is thickened forming the lens placode which becomes invaginated to form the lens vesicle at the mouth of the optic cup.
- (2) the lens vesicle separates from the surface ectoderm to lie at the mouth of optic cup.
- (3) the cells of the post-layer of the lens vesicle elongate to form the lens fibres which fill the cavity of the lens vesicle.



## (C) Development of the choroid & sclera :

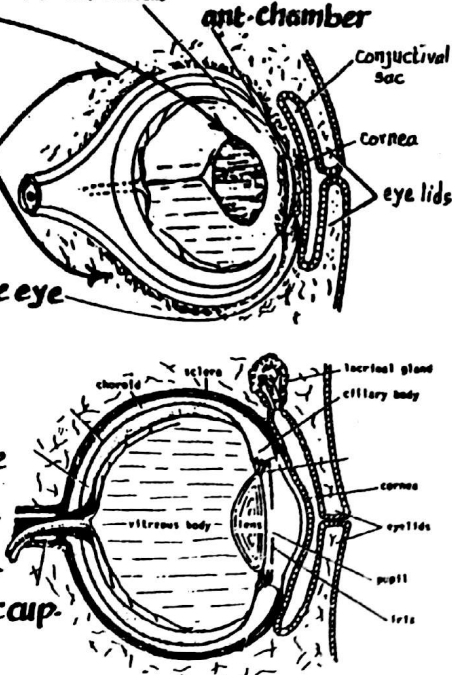
they develop from the mesenchyme around the optic vesicle.

## (D) Development of the cornea & ant-chamber :

the ant-chamber appears as a slit in the mesenchyme covering the eye anteriorly, splitting it into :

- (1) a superficial layer forming the main part of the cornea
- (2) a deep layer forming the irido-pupillary membrane covering the lens which degenerates later on.

**N.B :** (1) the surface epithelium of the cornea is derived from the ectoderm.  
 (2) the vitreous body is derived from the mesenchyme which fills the optic cup.



# Development of the ear

79

## (A) External ear

(I) The Auricle : develops from 6 mesenchymal swellings → around the post. part of the 1<sup>st</sup> pharyngeal cleft.

(II) Ext. auditory meatus : develops from the 1<sup>st</sup> pharyngeal cleft.

(III) Ear drum : consists of 3 layers

- (1) outer ectodermal layer : develops from the bottom of 1<sup>st</sup> ph. cleft.
- (2) inner endodermal layer : " from the tubotympanic recess
- (3) intermediate mesodermal layer : derived from the mesoderm in between the 1<sup>st</sup> cleft & 1<sup>st</sup> pouch.

## (B) Middle Ear

(I) Middle ear cavity : develops from the dorsal part of the tubo-tympanic recess which is derived from the 1<sup>st</sup> ph. pouch.

(II) Ossicles of the middle ear :

- Malleus & incus : derived from Meckel's cartilage of the 1<sup>st</sup> arch.
- Stapes : derived from Reichert's cartilage of the 2<sup>nd</sup> ph. arch.

(III) Muscles of the middle ear :

- (1) tensor tympani : derived from the 1<sup>st</sup> arch & supplied by mandibular n.
- (2) stapedius m. : derived from the 2<sup>nd</sup> arch & supplied by facial n.

## (C) Internal Ear

(I) The Membranous part : develops from ectoderm as follows :

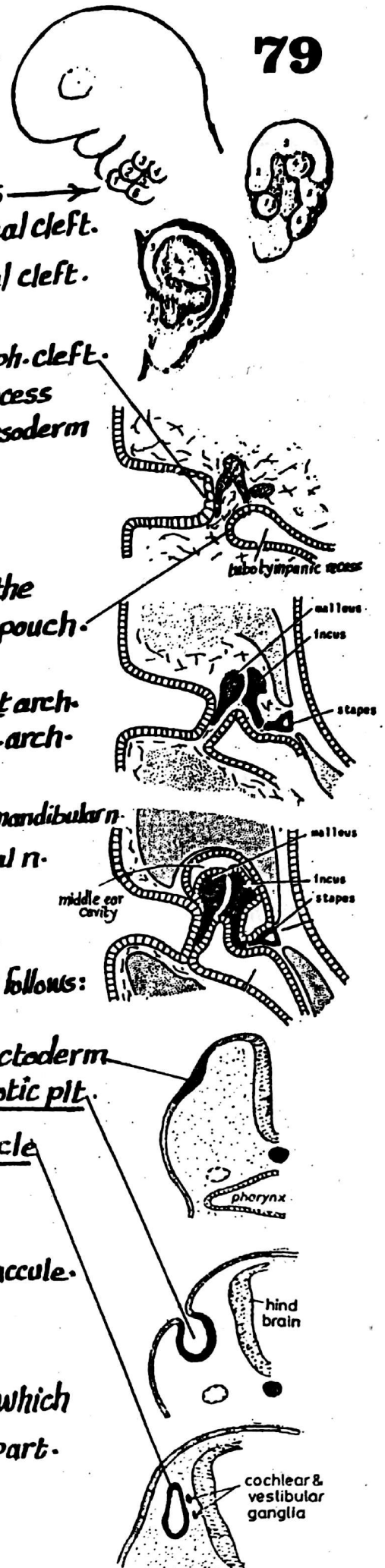
(1) Otic placode develops as thickened part of surface ectoderm opposite the hindbrain. It becomes invaginated forming otic pit.

(2) the otic pit separates from the surface forming otic vesicle

(3) the otic vesicle enlarges in a dorso-ventral direction & divides into :

- (a) ventral cochlear part which is coiled to form cochlea & saccule.
- (b) dorsal utricular part which forms the utricle & the 3 semicircular canals.

(II) The bony part : develops from the mesoderm which surrounds the membranous part.



# Development of the Pituitary gland

80

## Ant. lobe (adenohypophysis):

develops from the ectoderm of the roof of Stomodeum.

## post. lobe (neurohypophysis)

develops from the floor of the diencephalon (neural ectoderm).

### (1) A diverticulum called Rathke's pouch

grows upwards from the ectoderm of the roof of stomodeum in front of the bucco-pharyngeal membrane to form the ant. lobe of the pituitary gland.

### (2) The floor of the diencephalon sends a diverticulum called the Infundibulum which grows downwards in the direction of Rathke's pouch to form the post. lobe of the pituitary gland.

### (3) The infundibulum & Rathke's pouch meet together.

### (4) By the end of the 3<sup>rd</sup> month, the Rathke's pouch loses its connection with the stomodeum to form the ant. lobe of the pituitary & differentiates as follows:

- the ant. wall of Rathke's pouch develops into the pars distalis.
- an upward projection of pars distalis will form pars tuberalis.
- the post. wall of Rathke's pouch will form the pars intermedia.
- the lumen of Rathke's pouch becomes obliterated.

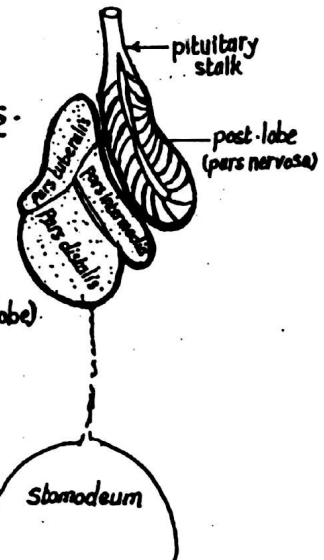
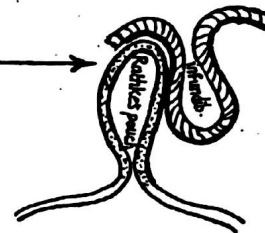
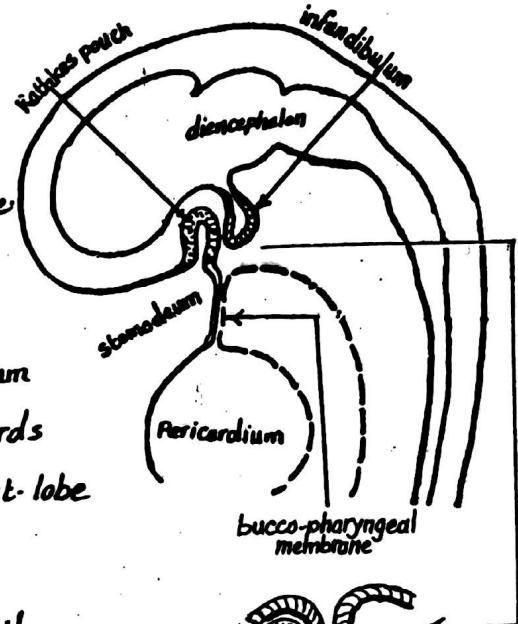
### (5) The infundibulum differentiates into the pars nervosa (post-lobe) & the pituitary stalk.

## \* Congenital anomalies of pituitary gland:

### (1) Agenesis: complete absence of the whole gland is a rare condition & is incompatible with life.

### (2) Absence of ant. lobe: due to failure of development of Rathke's pouch. This leads to maldevelopment of thyroid gland, suprarenal glands & the testes.

### (3) pharyngeal hypophysis: a remnant of Rathke's pouch remains attached to the pharyngeal wall





# Development of the Suprarenal glands

81

\* The Suprarenal gland is formed of Cortex & medulla which have different embryological origin

(1) the Suprarenal Cortex : is mesodermal in origin .

(2) the Suprarenal medulla : is ectodermal in origin .

\* The development proceeds as follows :

(1) During the 6<sup>th</sup> week, mesodermal cells of the Coelomic epithelium on either side of the mesentery of the gut proliferate to form a mass of large cells constituting the foetal cortex.

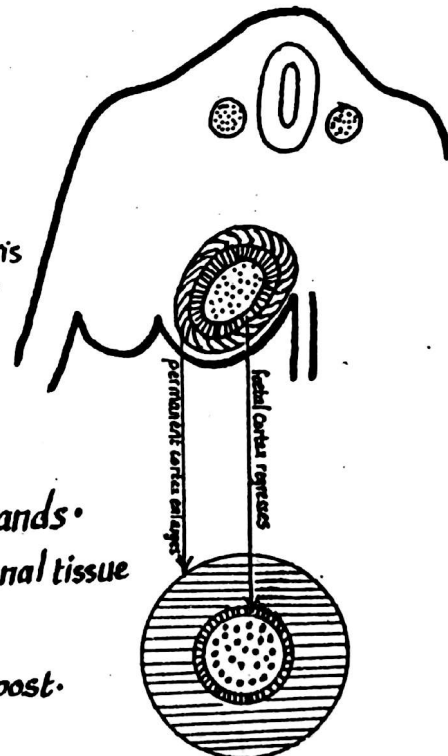
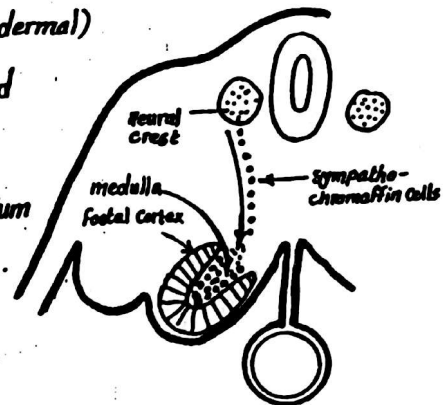
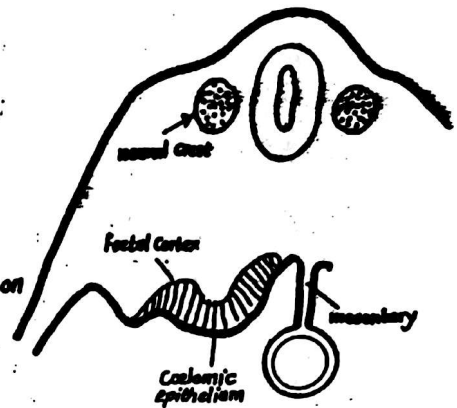
(2) Sympatho chromaffin cells from the neural crest (ectodermal) migrate to enter the medial aspect of the foetal cortex and develop to form the suprarenal medulla .

(3) A second layer of cells develop from the Coelomic mesothelium & surround the foetal cortex to form the permanent cortex.

(4) The foetal cortex regresses rapidly after birth being replaced by the permanent cortex.

(5) By the 3<sup>rd</sup> year after birth the foetal cortex disappears completely & the permanent cortex differentiates into 3 zones :

zona glomerulosa , zona fasciculata & zona reticularis however, full histological differentiation is attained at puberty.



## Congenital anomalies

(1) Agensis : failure of development of suprarenal glands .

(2) Ectopic suprarenal glands : occasionally suprarenal tissue is found beneath the capsule of the kidney .

(3) Accessory Cortical tissue : may be found on the post. abd. wall & pelvis behind the peritoneum .

(4) Adrenogenital syndrome : is a genetic disorder associated with excess A.C.T.H secretion by the pituitary leading to hypertrophy of suprarenal cortex & over production of androgens . It results in pseudohermaphroditism in the female & premature enlargement of the external genitali in the male .

# The Septum transversum

82

\* It is a thick mass of mesoderm which partially separates the thoracic cavity from the abdominal cavity.

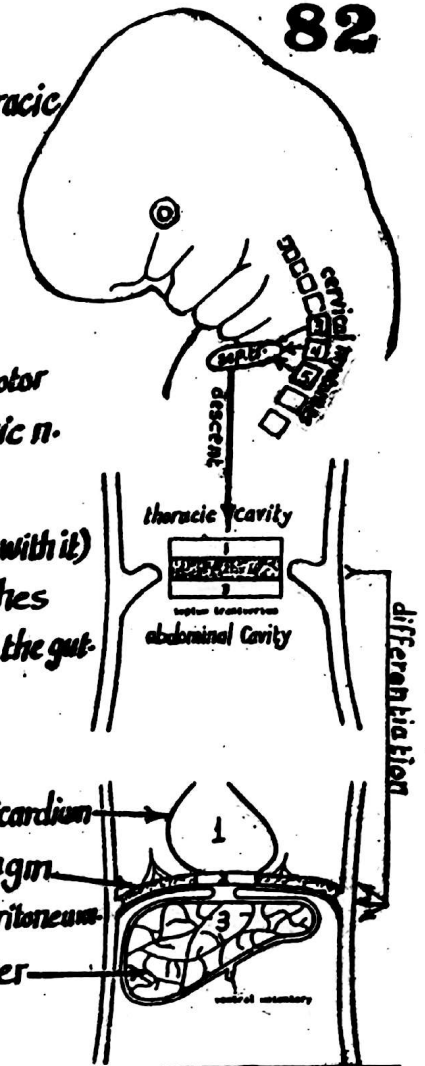
## \*Development :

- (1) the septum transversum is formed in the neck by fusion of the myotomes of the 3rd, 4th & 5th cervical segments & receives motor nerve supply from the 3rd, 4th & 5th cervical nerves via the phrenic n.
- (2) with folding of the embryonic disc & descent of the heart, the septum transversum is pushed caudally (pulling phrenic nerves with it) to reach the lower part of the thoracic cavity where it stretches horizontally from the ventral body wall to the dorsal mesentery of the gut.

## \*Derivatives :

the septum transversum becomes differentiated into 3 layers

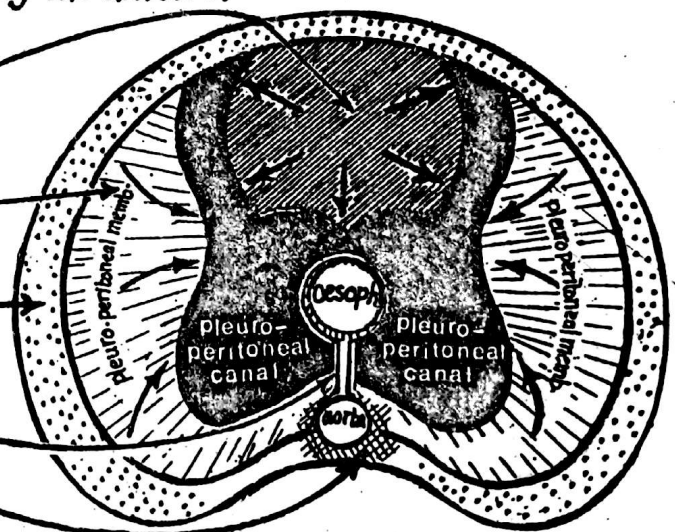
- (1) a superior layer which shares in the formation of the fibrous pericardium
- (2) a middle layer which forms the greater part of muscle of diaphragm & its central tendon + the diaphragmatic pleura & peritoneum
- (3) an inferior layer which forms the fibrous capsule & C-T of the liver & the ventral mesentery of the developing gut.



## Development of the Diaphragm

- \* The diaphragm is mesodermal in origin.
- \* It is formed between the 8th & 10th week by the union of the following mesodermal structures :

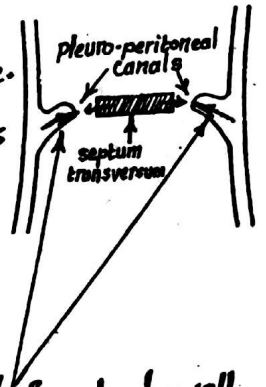
- (1) the septum transversum
- (2) 2 pleuro-peritoneal membranes
- (3) mesoderm from the chest wall.
- (4) mesentery of the oesophagus.
- (5) mesoderm around abdominal aorta.



\* The development of the diaphragm proceeds as follows :

## (1) Septum transversum :

- \* it is formed in the neck & descends to the lower part of the thoracic cavity (describe).
- \* it forms an incomplete septum between the thoracic & abdominal cavities since a pleuroperitoneal canal lies posterolateral to it on each side.
- \* the septum transversum expands & unites with the other components of the diaphragm to form: a large central part + the sternal & costal portions of the diaphragm.



## (2) the 2 pleuroperitoneal membranes :

- \* these are 2 mesodermal folds (one on each side) which project inwards from body wall.
- \* they grow medially encroaching on the pleuro-peritoneal canals until they finally fuse with the septum transversum & the mesentery of the oesophagus thus closing the pleuroperitoneal canals.
- \* the pleuroperitoneal membranes form the dorsolateral parts of the diaphragm.

(3) Mesoderm of the chest wall : grows inwards forming the marginal part of the diaphragm on either side of the pleuroperitoneal membrane.

(4) Mesentery of the oesophagus : forms the dorsal median part of the diaphragm (between the oesophagus & aorta).

(5) the mesoderm around the aorta : forms the lumbar (vertebral) part of the diaphragm.

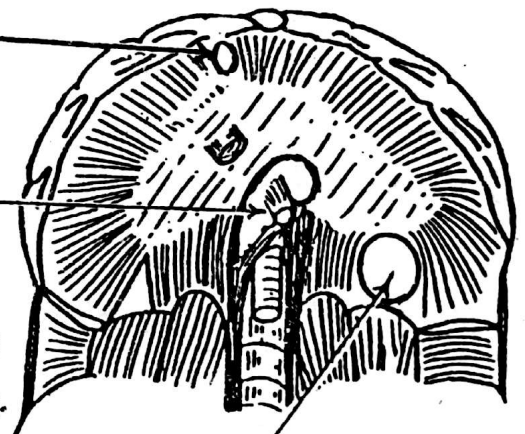
## Congenital anomalies of the diaphragm

### (1) parasternal hernia of Morgagni :

it is due failure of development of a small part of the diaphragm between the sternal & costal parts.

### (2) Congenital hiatus hernia (oesophageal) hernia :

due to widening of the oesophageal hiatus of the diaphragm & Congenital shortening of the oesophagus leading to protrusion of the stomach into the thorax.



### (3) Congenital diaphragmatic hernia of Bochdalek :

due to failure of the pleuro-peritoneal membranes to close the pleuroperitoneal canals allowing the abdominal viscera to enter the pleural cavity & compress the lungs & heart. It is more common on the left side.

## 1-- DEVELOPMENT OF THE SKULL

### (A) Chondro-cranium (base of skull)

develops by cartilagenous ossification  
in 6 pairs of Cartilages: 3 lateral &  
3 medial as follows:

### (B) Viscerocranium (roof & sides)

develops by membranous ossification forming  
the frontal, parietal, squamous temporal, squamous  
occipital in addition to the facial bones

#### the 3 lat. Cartilages

(1) the orbito sphenoid:

Forms the lesser wing  
of sphenoid

(2) the ali-sphenoid

Forms the greater  
wing of sphenoid

(3) the peri-otic capsule

Forms the petrous &  
mastoid parts of the  
temporal bone

#### the 3 med. Cartilages

(1) trabeculae Cranii:

Fuse to form the ethmoid  
bone

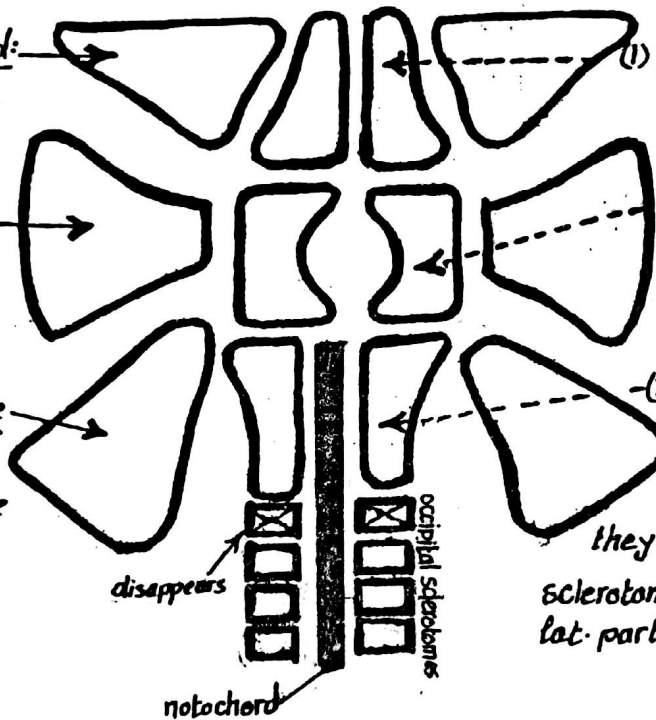
(2) hypophyseal Cartilages

lie in front of the prochordal  
plate & fuse to form the  
body of sphenoid

(3) para Chordal cartilages

(formed of the mesenchyme  
around the cephalic part of  
the notochord):

they fuse with the 3 occipital  
sclerotomes to form the basilar &  
lat. parts of occipital bone



#### N.B

(1) the skull bones which develop in membrane are: frontal, parietal, maxillary, zygomatic,  
nasal, lacrimal & palatine

(2) the skull bones developing from Cartilage are: ethmoid & conchae of the nose

(3) the skull bones developing from both Cartilage & membrane are:

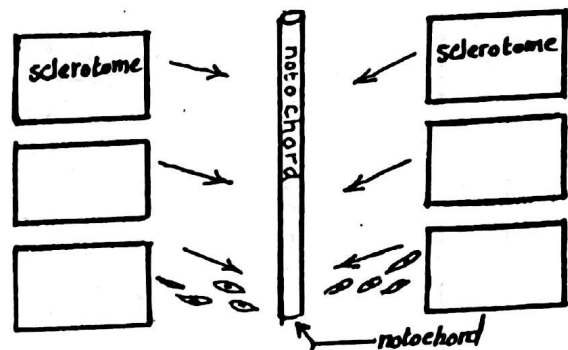
occipital, sphenoid & temporal bones



## 2-- DEVELOPMENT OF THE VERTEBRAL COLUMN 85

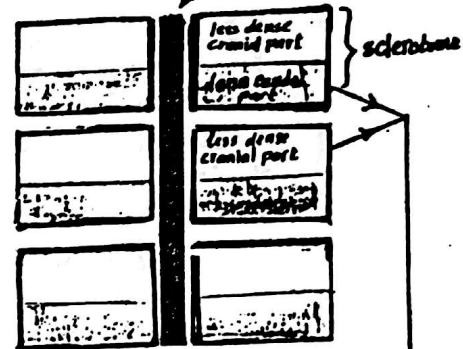
### (1) Stage of notochord:

- \* the notochord is a primitive axial skeleton which consists of a rod of cells surrounded by a strong sheath.



### (2) Mesenchymal vertebral column:

- \* During the 4th week, sclerotome cells migrate medially to surround the notochord forming the mesenchymal vertebral column.
- \* Each mesenchymal vertebra is formed of the caudal  $\frac{1}{2}$  of one sclerotome + the cranial  $\frac{1}{2}$  of the next sclerotome.
- \* The notochord regresses completely in the region of the vertebral bodies but enlarges in the region between the bodies to form the nucleus pulposus of the future intervertebral disc.

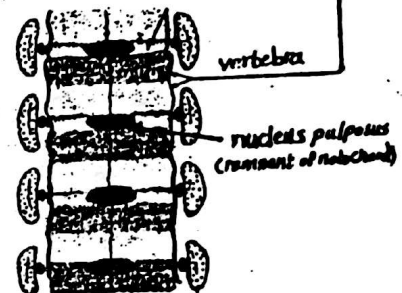


### (3) Cartilagenous vertebral Column:

- the mesenchymal vertebral bodies are changed into cartilage

### (4) bony vertebral column:

- Centre of ossification appears in the body of each vertebra thus the cartilagenous vertebral column is changed into bony V.C

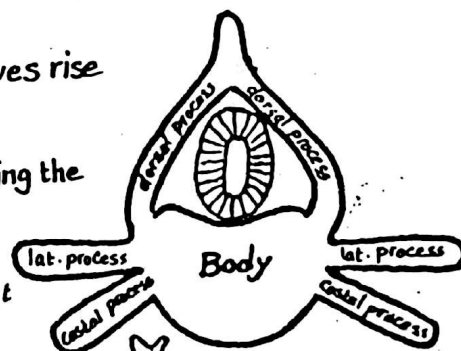


**N.B:** during development, the vertebral body gives rise to 3 pairs of processes

- (1) 2 dorsal processes: surround the neural tube forming the 2 laminae then unite posteriorly forming the spine.

- (2) 2 lat. processes
  - (3) 2 Costal processes
- their fate differs in the different regions of the V. column as follows:


- (a) in the cervical region: they unite around the f. transversarium



- (b) in the thoracic region: the Costal element elongates forming the rib



- (c) in the lumbar region: the 2 elements remain fused, the Costal element forming the ant. part of the tr. process



- (d) In the Sacrum: the 2 parts remain fused forming the lat. mass of the sacrum.

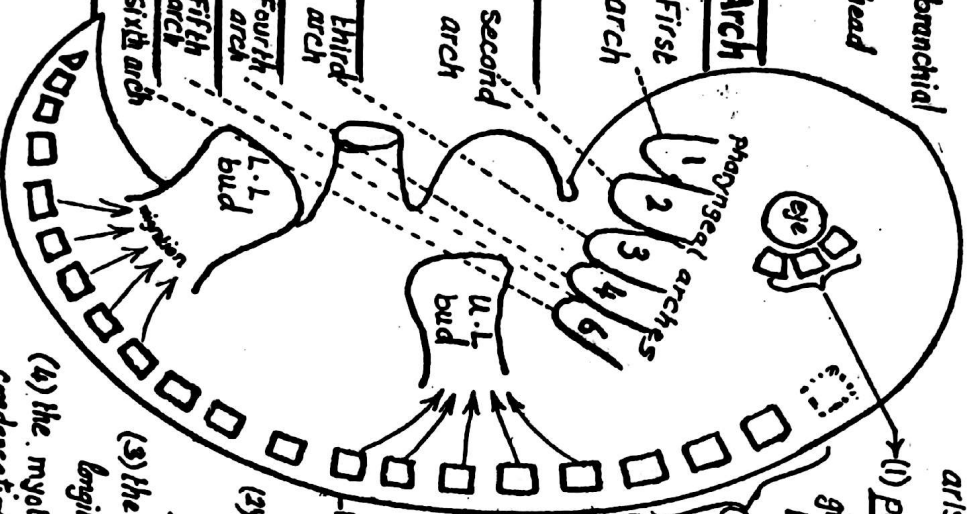


### 3-- DEVELOPMENT OF SKELETAL MUSCLES

#### Branchiomeric muscles

arise from the mesoderm of the branchial arches and give certain muscles in the head & neck

Muscles	Arch
(1) The 4 muscles of mastication	First arch
(2) mylohyoid + ant. belly of digastric	
(3) tensor palati + tensor tympani	
(1) all muscles of face & scalp	Second arch
(2) stylohyoid + post. belly of digastric	
(3) stapedius m.	
one m. of pharynx: stylopharyngeus	Third arch
one m. of larynx: cricothyroid m.	Fourth arch
Degenerates	Fifth arch
intrinsic muscles of larynx	Sixth arch



#### Myotomic muscles

arise from myotomes (the dorsolateral parts of the somites) as follows:  
 (1) Periocular myotomes (from mesoderm around the prechordal plate) give the muscles of the eye except the iris muscles which arise from the neural ectoderm of the optic cup.

(2) Occipital myotomes: give the muscles of the tongue

(3) the remaining myotomes give rise to the muscles of the neck, trunk & limbs as follows

- each myotome divides into a small dorsal part called the epimere (gives the extensor mm. of the back) & a large ventral part called hypomere (gives lat. & ventral flexor muscles) as follows:

(1) - the hypomeres may split longitudinally

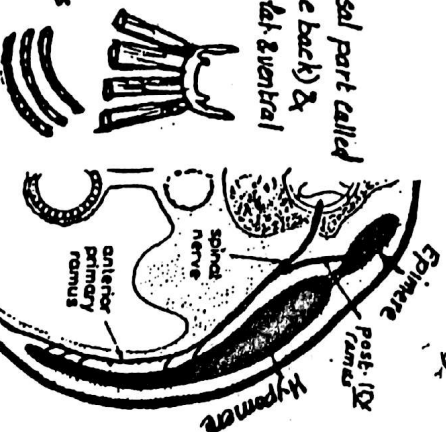
e.g. the infrahyoid muscles

(2) they may split laterally to form layers

e.g. the external, internal & transversus muscles of thorax & abdomen.

(3) the ventral tips of successive hypomeres may unite to form longitudinal muscles: e.g. rectus abdominis m.

(4) the myotomes may migrate to the base of the limb buds forming mesenchyme condensation which divides into ventral flexor & dorsal extensor groups of muscles

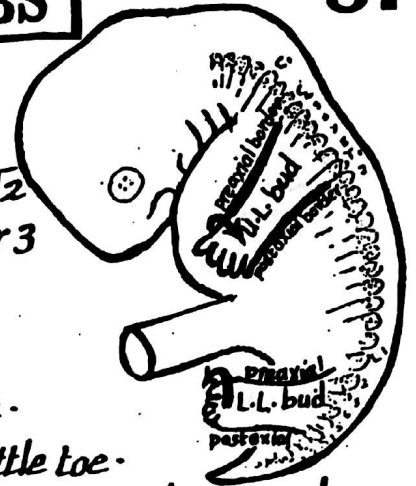


# DEVELOPMENT OF THE LIMBS

87

## (1) development of limb buds :

- time : they appear at the beginning of the 5<sup>th</sup> week.
- site : the U.L. bud develops opposite the segments C4 to T2
- the L.L. bud " " the lower 4 lumbar & upper 3 sacral segments



- shape : each limb bud is flattened, having 2 borders :

- preaxial (cranial) border : marked by the thumb or big toe.
- postaxial (caudal) border : marked by the little finger or little toe.

- Structure : each limb bud is composed of mass of mesoderm covered by ectoderm.
- The mesoderm is derived from : (a) lat. plate mesoderm (b) migrating myotomes.

## (2) Differentiation of the mesoderm into bones & muscles :

- the central (axial) mesoderm forms cartilagenous skeleton which will ossify into bones.
- the surrounding mesoderm (derived from myotomes) gives the muscles as follows :
  - the ventral mesodermal mass develops into the flexor & adductor muscles & derives its nerve supply from the ant. divisions of the ventral 1<sup>st</sup> 8 rami of spinal nerves
  - the dorsal mesodermal mass develops into the extensor & abductor muscles & are supplied by the post. divisions of the ventral 1<sup>st</sup> 8 rami of spinal nerves.

## (3) Segmentation of the limb bud:

creases appear in each bud dividing it into 3 segments

- arm, forearm & hand (in the U.L.)
- thigh, leg & foot (in the L.L.)

## (4) Rotation of the limb buds : occurs in the 7<sup>th</sup> & 8<sup>th</sup> weeks as follows

- the U.L. is adducted & rotated laterally thus the preaxial border & thumb become directed laterally.
- the L.L. is adducted & rotate i medially thus the preaxial border & the big toe become directed medially.

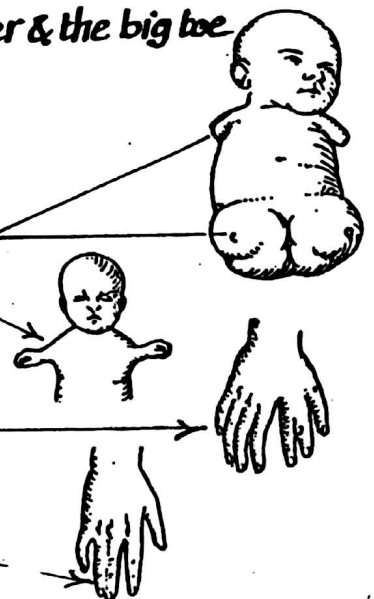
## Congenital anomalies of the limbs

(1) Amelia : complete failure of development of one (or more) limb

(2) Focomelia : the hand or the foot is attached directly to the trunk due to absence of the proximal part of the limb

(3) polydactyly : the presence of extra fingers or toes

(4) Syndactyly : fusion of 2 fingers or toes.



# DEVELOPMENT OF THE SKIN

88

\* The Skin Consists of 2 Components (epidermis & dermis) which arise from 2 sources:

(I) the Epidermis: arises from the surface ectoderm

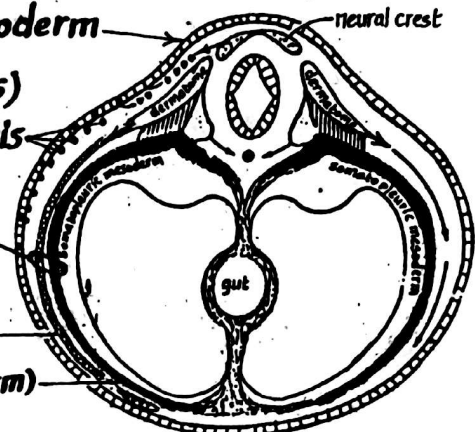
& receives melanoblasts (melanin secreting cells) which migrate from the neural crest to the epidermis

(II) the Dermis & subcutaneous tissue:

are mesodermal and arise from 2 sources:

(1) the mesoderm of the dermatomes of the somites

(2) the somatopleuric mesoderm (part of lat. plate mesoderm)



(III) the Hair:

(1) The hairs begin to develop in the 3rd month as solid ectodermal buds arising from the epidermis

(2) the hair buds sink into the underlying mesenchyme & its lower end becomes swollen to form the hair bulb

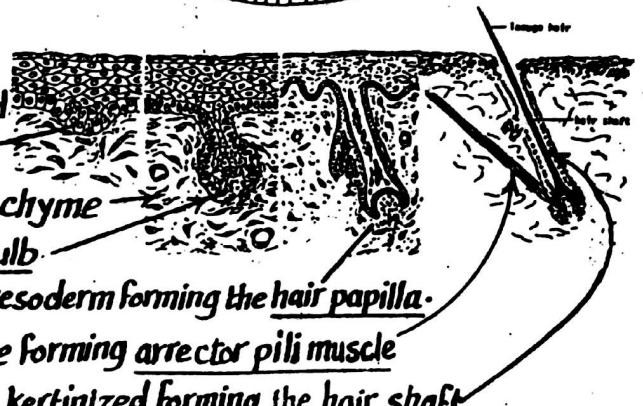
(3) the hair bulb becomes invaginated by a mass of mesoderm forming the hair papilla

(4) muscle fibres become attached to the hair follicle forming arrector pili muscle

(5) the central cells of the hair bulb elongate & become keratinized forming the hair shaft

(6) the first hairs which appear on the foetus are fine & called lanugo hairs

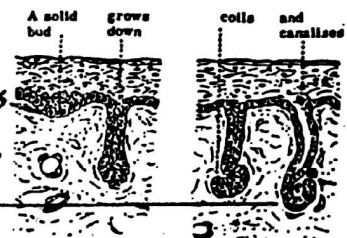
(7) at birth, the lanugo hairs degenerate & are replaced later by coarser hairs.



IV- skin glands (sebaceous & sweat glands):

(A) Sweat glands: appear in the 5th month as solid downgrowths from the surface ectoderm into the underlying mesenchyme.

Later on, they canalize & their terminal ends become convoluted



(B) the Sebaceous glands: arise as side branches from the buds of the hair follicles then their central cells degenerate forming fatty secretion

that passes out into the hair follicles.

## Congenital anomalies

(1) ichthyosis: dry scaly skin (hereditary disease)

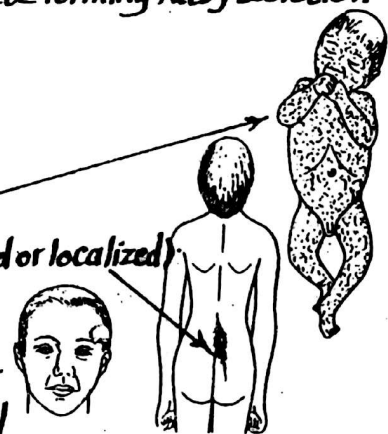
(2) hypertrichosis: excessive formation of hairs (generalized or localized)

(3) Atrichia: congenital absence of hair.

(4) Sequestration dermoid:

this is a congenital cyst caused by burying of ectodermal

cells deep to the surface at the lines of closure of embryonic clefts (see p.70).



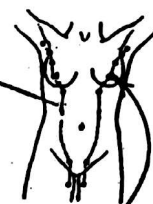

# Development of the mammary gland

89

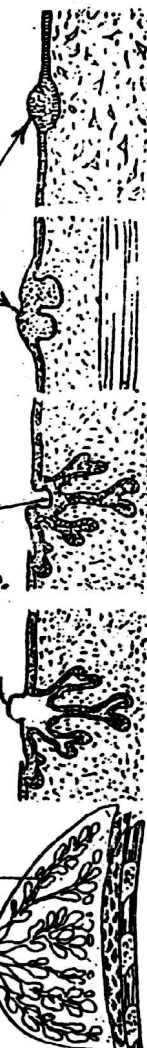## (I) Appearance of a milk line (ridge):

- In the young embryo, a linear thickening of the surface ectoderm (called the milk line) appears on the ventral body wall extending from the axilla down to the medial part of the inguinal region.
- the line disappears shortly after its formation except for a localized area in the pectoral region which develops into the mammary gland as follows:



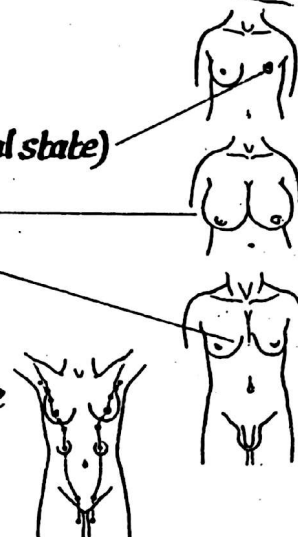
## (II) Formation of the glandular tissue:

- (1) 15-20 solid ectodermal buds arise from the remaining part of the milk line
- (2) the buds form solid cords which grow into the underlying mesenchyme.  
(Each cord represents a futur milk duct & a lobe of the mammary gland).
- (3) the cords continue to grow & branch throughout the foetal life.
- (4) shortly before birth, the cords become canalized to form the lactiferous sinuses, lactiferous ducts & secretory alveoli
- (5) the lactiferous ducts open into a depressed area on the surface.
- (6) shortly after birth this depressed area becomes elevated forming the nipple.
- (7) At puberty the following occur:
  - (a) In the male: the mammary gland remains rudimentary (glandular tissue consisting of ducts only without alveoli).
  - (b) In the female: under the effect of the ovarian hormones, the mammary gland enlarges in size due to more branching in the lactiferous ducts & deposition of more fat between the lobules of the gland.



## Congenital anomalies

- (1) Amastia: absence of one or both mammary glands.
- (2) micromastia: abnormally small breast (retention of prepubertal state)
- (3) macromastia: abnormally large breast
- (4) gynaecomastia: a male developing a female type of breast
- (5) polymastia: the presence of accessory breast. } any where
- (6) polythelia: " " " " nipple } along the mammary line
- (7) Inverted nipple: due to failure of elevation of the mammary pit.



# **Index of Contents**

1-	<b>Development of the Heart.....</b>	<b>1-14</b>
2-	<b>Development of the Arteries .....</b>	<b>15-21</b>
3-	<b>Development of the Veins .....</b>	<b>21-25</b>
4-	<b>Foetal circulation.....</b>	<b>26-28</b>
5-	<b>Digestive &amp; Respiratory Systems.....</b>	<b>29-49</b>
6-	<b>Urinary System.....</b>	<b>50-57</b>
7-	<b>Genital System.....</b>	<b>58-66</b>
8-	<b>Development of the Face.....</b>	<b>67-68</b>
9-	<b>Development of the Palate.....</b>	<b>69-70</b>
10-	<b>Development of the Central Nervous System.....</b>	<b>71-77</b>
11-	<b>Development of the Eye.....</b>	<b>78</b>
12-	<b>Development of the Ear.....</b>	<b>79</b>
13-	<b>Development of the Pituitary Gland .....</b>	<b>80</b>
14-	<b>Development of the Suprarenal Gland.....</b>	<b>81</b>
15-	<b>Septum transversum &amp; the diaphragm .....</b>	<b>82-83</b>
16-	<b>Development of the Skull .....</b>	<b>84</b>
17-	<b>Development of the Vertebral Column .....</b>	<b>85</b>
18-	<b>Development of the Skeletal Muscles .....</b>	<b>86</b>
19-	<b>Development of the Limbs.....</b>	<b>87</b>
20-	<b>Development of the Skin.....</b>	<b>88</b>
21-	<b>Development of the Mammary Gland. ....</b>	<b>89</b>

\*\*\*\*\*